




Laser & Health
ACADEMY

Compendium of NightLase[®] and
other Otolaryngology Applications
Scientific Research on Fotona's Laser Technology



Foreword

Scientific Evidence Behind NightLase® and Other Otolaryngology Applications

For decades, Fotona has been a pioneer in laser technology, pushing the boundaries of innovation and setting new standards in medical treatments. Within these pages, we present a compilation of peer-reviewed studies and clinical trials exploring the potential of Er:YAG and Nd:YAG lasers in otolaryngology applications.

The compendium contains summaries of key findings from selected publications, providing solid scientific evidence to support the safety and efficacy of NightLase® and other laser-assisted otolaryngological therapies. We have added QR codes to all summaries for easier access to the official online sources.


Particularly notable in this collection is the unique non-ablative, patented Fotona SMOOTH® technology - a manifestation of Fotona's commitment to advancing minimally invasive nonsurgical laser treatments.

Throughout its 60-year history, Fotona has continually developed laser technology based on stringent research and hard scientific evidence. We believe this overview will help bring critical medical discoveries one step closer to users. We also hope it will inspire researchers to further examine the nuances of laser applications in sleep-disordered breathing, snoring, and related otolaryngological conditions.

The LA&HA Clinical Affairs Team

The use of lasers for medical treatments is subject to local regulations, which may vary depending on your region. Please check with the manufacturer whether a specific product or application has been approved or cleared to be marketed in your country.





Short Drafts of Selected Scientific Publications

Er:YAG Laser for Snoring: A Systemic Review and Meta-Analysis

Authors: C. Neruntarat, K. Khuancharee, & P. Shoowit

Published in: *Lasers in Medical Science*. 2020. <https://doi.org/10.1007/s10103-020-02987-3>

Objective A new outpatient non-surgical method using Er:YAG laser for snoring has been demonstrated. The aim of this systematic review and meta-analysis was to investigate the effects of this treatment on snoring.

Method 1548 relevant articles were searched from various databases from 1 January 2000 to September 2018 including PubMed, MEDLINE, EMBASE, Cochrane Library, Web of Science, and Scopus and reference lists. Meta-analysis was performed with RevMan software. Cochran's Q and I² statistics were used to assess heterogeneity. The overall effect was evaluated using z-tests. Seven studies and 247 participants treated with two to three sessions of Er:YAG 2940 nm laser (long pulse mode, 10 Hz, fluence 1.6 J/cm²) were included.

Results There was a statistically significant reduction of pooled snoring VAS (mean difference (MD) (95% CI), -6.89 (-7.62, -6.15)). Patient satisfaction rate after laser treatment was 80% (95% CI, 70.69, 89.05) of cases. A widening of the upper airway dimension was revealed; however, changes in apnea-hypopnea index (AHI) and respiratory disturbance index (RDI) were not significantly different. Mean follow-up period was 3 to 36 months. Patients tolerated the procedure well without anesthesia. There were minimal side effects without serious adverse effects.

Conclusion Er:YAG laser is shown to be effective in a way to reduce snoring without significant AHI or RDI changes. However, randomized controlled trials, objective data, multicenter cooperation, and long-term outcomes are needed to confirm the benefits of this laser for snoring.



Use of Laser in Sleep Disorders: A Review on Low Laser Uvulopalatoplasty

Authors: M. Kakkar, S. Malik, B. Gupta, N. Vaid, R. George, & S. Singh
Published in: *Sleep Disorders*. 2021. <https://doi.org/10.1155/2021/8821073>

Objective The objective of this study was to find the effectiveness of the low laser therapy on uvulopalatoplasty/soft palate in sleep apnea patients and snoring. Also, this study aims to touch base on the effectiveness of the Er:YAG and combined use of Er:YAG and Nd:YAG lasers for the uvulopalatoplasty.

Methods A comprehensive and systematic literature review was conducted using PubMed, Google Scholar, Cochrane Central Register of Controlled Trials, Embase, Web of Science, the US National Institutes of Health Trials Registry, WHO Library, and Medline. The search strategies were developed to cover publications from January 2010 through March 2020. The past 10 years of the search were performed to report the data following systematic review and meta-analysis protocol (PRISMA-P) 2015 statement.

Results With the help of keywords, the total number of abstracts identified was 946. These abstracts were further reviewed as per inclusion and exclusion criteria, and 106 abstracts were identified to match the selection criteria. Further review of full articles resulted in 12 articles that matched the inclusion criteria for the study.

Conclusion Er:YAG can be a good alternative and the least invasive therapy for managing snoring and obstructive sleep apnea. Er:YAG therapy is considered to be a nonsurgical intervention with minimum side effects and can be performed chairside.



Treatment of Snoring Using a Non Invasive Er:YAG Laser with SMOOTH Mode (NightLase): A Randomized Controlled Trial

Authors: V. A. Picavet, M. Dellian, E. Gehrking, A. Sauter, & K. Hasselbacher

Published in: *European Archives of Oto-Rhino-Laryngology*, 2022. <https://doi.org/10.1007/s00405-022-07539-9>

Objectives The aim of this study was to assess safety and efficacy of a non-invasive 2940 nm Er:YAG treatment with SMOOTH mode in reducing snoring in adult patients and to compare its efficacy and safety to sham treatment in a randomized controlled trial setting.

Methods 40 primary snoring patients (≥ 18 year, $AHI < 15e/h$, $BMI \leq 30$) were randomized to receive either 3 sessions of NightLase or sham laser treatment. The main outcome measures were Snore Outcomes Survey (SOS), the Spouse/Bed Partner Survey (SBPS), a visual analogue snoring scale (bed partner) and a visual analogue pain scale.

Results NightLase was well tolerated, no local anesthesia was required (mean VAS pain score in NightLase group= 3.0 ± 1.7). No complications occurred. SOS, SBPS and VAS snoring scores improved in the NightLase group (33.7 ± 14.1 to 56.2 ± 16.1) (35.0 ± 17.1 to 61.5 ± 16.4) and (7.9 ± 2.0 to 4.7 ± 2.8) while no change was recorded in the sham group (32.2 ± 14.5 vs 32.1 ± 13.0) (36.7 ± 12.1 vs 34.7 ± 12.7) (8.1 ± 1.7 vs 8.0 ± 1.6), respectively.

Conclusions NightLase is a safe, minimally invasive treatment that significantly reduced snoring compared to sham treatment.

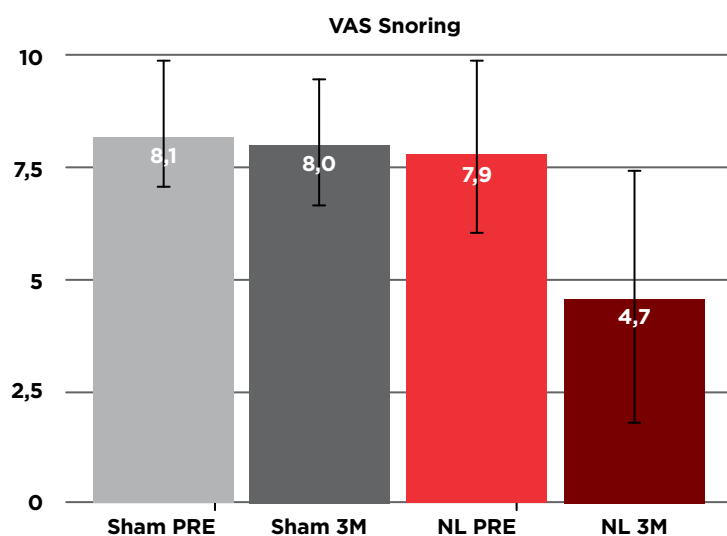


Fig. 3 Mean visual analogue snoring scores as assessed by the bed partner remained unchanged in the sham group 8.1 ± 1.7 vs 8.0 ± 1.6 while it improved in the **NightLase**[®] group from 7.9 ± 2.0 preoperative to 4.7 ± 2.8 at 3 months (M) postoperative.



A Long-Term Follow-up Study for the Treatment of Snoring after Using Patterned Non-Ablative Erbium: YAG 2,940 nm Laser

Authors: A. N. Kassab, A. E. Kharbotly, A. A. Elsamie, & M. R. Ahmed

Published in: *Int Arch Otorhinolaryngol.* 2022. doi <http://doi.org/10.1055/s-0042-1744171>.

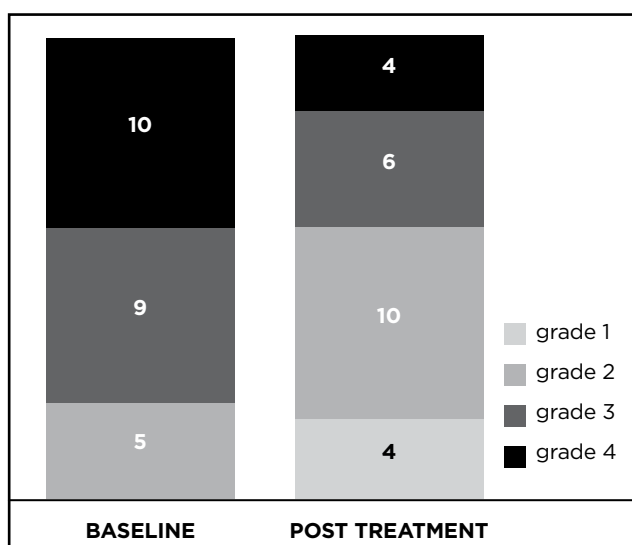
Introduction Laser uvulopalatoplasty is an established operation for the treatment of snoring with good results on a short-term basis, while long-term follow-up studies, in addition to their scarcity, had conflicting results regarding recurrence, the change of snoring quality, and complications.

Objective To assess the long-term follow-up results of using nonablative 2,940 nm Erbium: YAG for the treatment of snoring regarding outcomes and recurrence.

Methods This 2-year follow-up study was conducted on 76 patients operated upon by non-ablative 2940 nm Erbium: yttrium-aluminum-garnet (Er:YAG) using a PS01 patterned handpiece. Subjective evaluation of the treatment was performed relying on a smartphone application to record snoring in addition to a questionnaire specially designed to report recurrence and change in the quality of snoring reported by a patient's spouse. The objective evaluation was done by computed tomography (CT) imaging of the soft palate. The patients were evaluated preoperatively, 6 weeks postoperatively and after a 2-year follow-up period.

Results Six week after the procedure, there was a significant improvement in 52 patients (68.4%). Out of the 52 patients, only 43 completed the 2-year follow-up; however, 15 of them complained of recurrence. Nevertheless, the patients who suffered from recurrence showed subjective improvement in snoring quality.

Conclusions The nonablative mode of Erbium: YAG 2,940 nm laser proved to be efficient in soft palate tightening for the management of snoring. However, there was recurrence in 34.8% of the patients who presented objective and subjective improvement of the complaints, 6 weeks postoperatively and after a 2-year follow-up period.



Average change - 0.79 grade. Median change - 1 grade



Nonsurgical Minimally Invasive Er:YAG Laser Snoring Treatment

Authors: K. Miracki & Z. Vizintin
Published in: Journal of the Laser and Health Academy. 2013. Vol. 1, pp. 36-41.

Objective This report describes a one year clinical experience performing the NightLase™ laser treatment on patients with snoring and other SDB symptoms. The NightLase treatment is based on a minimally invasive photothermal effect using Er:YAG laser light on oral mucosa.

Method In a period of one year we treated 57 patients having snoring and other SDB symptoms. All patients received three sessions of the NightLase laser treatment. Discomfort during the treatment was evaluated by the patients and potential side effects were monitored.

Results Results were measured using a snoring questionnaire during follow-ups at 14 days and 45 days. Long-term effects for up to 15 month after the treatment were followed up on by performing telephone interviews. The majority (74%) of patients responded positively to the treatment, with an average improvement of snoring severity and SDB scores of 50% and 45.9%, respectively. Only mild discomfort during the treatment was recorded, and there were no other adverse effects.

Conclusion The NightLase Er:YAG laser method has been found to be an effective, minimally invasive and safe method for treating patients with snoring and other SDB symptoms.

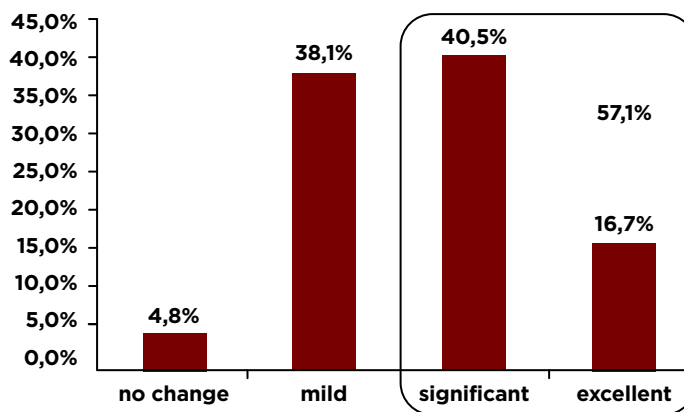


Fig. 6: Improvement of snoring assessed by patients: 95.2% of patients recognize improvement of their snoring, with 57.1% evaluating it as significant or excellent.

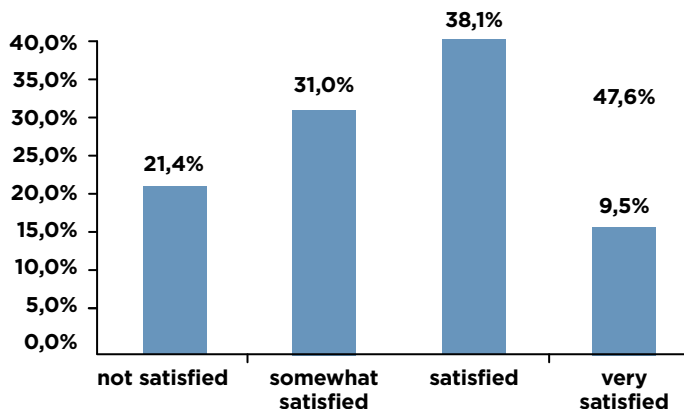


Fig. 7: Patients' satisfaction with the treatment and the results - 79.6% of patients expressed satisfaction with the treatment. Almost half of them (47.6%) assessed their evaluation as satisfied and very satisfied.



Outpatient Erbium:YAG (2940 nm) Laser Treatment for Snoring: A Prospective Study on 40 Patients

Authors: I. Storchi, S. Parker, F. Bovis, S. Benedicenti, & A. Amaroli

Published in: Lasers in Medical Science. 2018. <https://doi.org/10.1007/s10103-018-2436-6>

Introduction Snoring is a sleep phenomenon due to the partial upper airway obstruction during sleep, which causes vibration of the tissues of the rhino-oro-hypopharynx and less frequently the larynx.

Objective This study evaluated the use and effectiveness of the erbium:YAG 2940 nm laser as an adjunctive in providing treatment for patients suffering from chronic snoring-related sleep disorders.

Methods A prospective study of 40 consecutive patients with snoring and sleep disorders was performed, assessing data before and after three Er:YAG laser treatment sessions.

Results During laser treatment, pain was almost absent. There were no side effects, except a very mild sore throat in 1 out of 40 patients. The patient's evaluation of satisfaction of the results obtained after the treatments showed that 85% of cases were very satisfied, 5 patients (12.5%) reported being fairly satisfied with the treatment and only 1 subject (2.5%) was not satisfied. Mallampati, Friedman Tongue Position, and degree of O (oropharynx) at nose oropharynx hypopharynx and larynx classification were significantly decreased after the laser sessions. The decrease of Epworth Sleepiness Scale and Visual Analogue Scale for loudness of snoring, waking up during sleep because of snoring, dry mouth on waking, and choking were all statistically significant. The incidence of dreaming during the night also raised significantly; 30/40 (75%) of cases perceived less tightness in their throat and better breathing after treatment.

Conclusion These results were stable at 20 months follow-up (14-24 q) in 72% of cases. Nonsurgical and non-invasive Er:YAG laser treatment demonstrated to be a valid procedure in reducing the loudness of snoring.

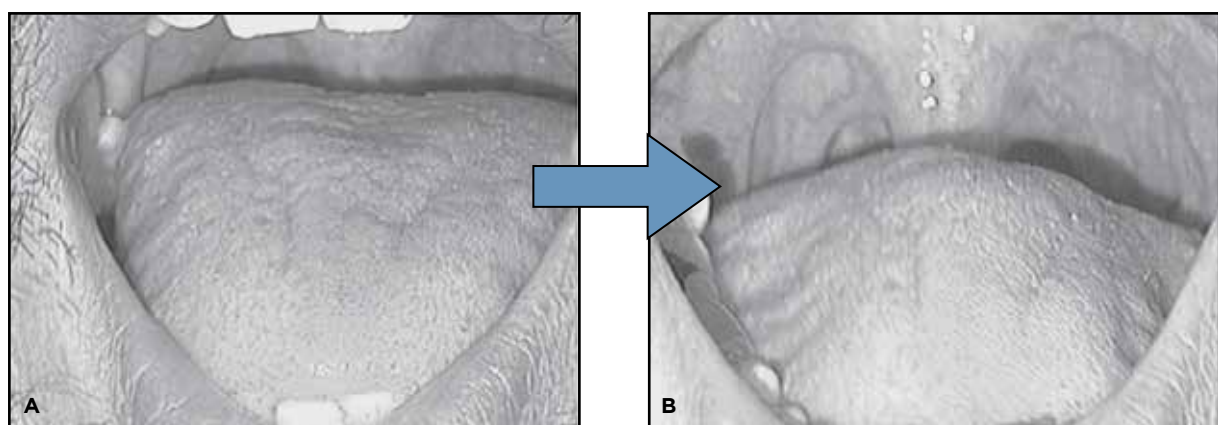

Fig. 3 Improvement of FTP from grade 3 (A) to grade 2 (B)



Er:YAG Laser Treatment of Simple Snorers in an Outpatient Setting

Authors: E. Cetinkaya, M. Turker, K. Kiraz, & H. Gulkesen

Published in: ORL 2016, DOI: 10.1159/00044351

Objectives Snoring occurs as a result of soft tissue vibration caused by a partial upper airway collapse during sleep. This study evaluated the effectiveness and potential adverse side effects associated with the use of a nonsurgical, erbium-doped yttrium aluminum garnet (Er:YAG) laser treatment for patients with snoring conditions.

Materials and Methods In total, 33 patients with different degrees of snoring were analyzed retrospectively. All patients received three NightLase® Er:YAG laser treatments. Results were measured using a follow-up questionnaire and then statistically analyzed. Any effects that occurred during the first year after treatment (i.e., short-term effects) were followed up with interviews.

Results Laser treatment effectively reduced patients' snoring and achieved a 65% satisfaction rate after three treatments. The greatest improvement and satisfaction were experienced by patients aged ≥ 50 years. Patients reported additional benefits from this treatment including easier breathing, higher alertness, and increased focus.

Conclusions Nonsurgical Er:YAG laser treatment is an effective and minimally invasive procedure to reduce patient snoring and other sleep-disordered breathing symptoms. Patients reported minimal disadvantages including minor discomfort and a low risk of side effects.

Age group (years)	improvement score			
	minimum	maximum	mean	standard deviation
I (25-34)	3	7	5.2	1.3
II (35-49)	5	12	7.9	2.2
III (50-70)	9	16	12.6	2.2

Statistically significant differences were observed between Groups I and II ($p=0.009$) as well as between Group III and Group I and II ($p<0.009$)

Table. 3 Descriptive statistics of improvement score [pre-application score–post-application score] according to age groups



Minimally invasive erbium laser treatment for selected snorers

Authors: H. Frelich, W. Scierski, M. Markow, J. Frelich, H. Frelich, & M. Maciej

Published in: *Lasers in Medical Science*, 2019 <https://doi.org/10.1007/s10103-019-02731-6>

Objective The aim of this paper is to present our results and experience in the treatment of snoring using the non-ablative Erbium: Yttrium Aluminum Garnet (Er:YAG) laser.

Method Twenty-four patients (18 male and 6 female) with snoring problems due to soft palate hypertrophy were treated with 3 treatment procedures with Er:YAG 2940 nm laser (long pulse mode, 10 Hz, fluence 1.8 – 2.0 J/cm²) performed at 2-week intervals. The treatment procedures were performed in outpatient settings. One treatment session lasted 15–20 min. Subjective (questionnaires) and objective (polygraph) outcome measures were assessed at baseline and 3 months after the final laser treatment. Wilcoxon Signed Rank was used to compare before and after scores.

Results All polygraph variables showed some improvement 3 months after the end of treatment; however, only the reduction of the number of hypopnea episodes per hour was statistically significant ($p = 0.034$). In 13/24 patients, snoring time accounted for less than 5% of the sleep time after the treatment compared to 6/24 patients at baseline. The questionnaire survey showed statistically significant improvement in the quality of sleep and life of the patients as well as their partners after Er:YAG treatment ($p < 0.001$). The assessment of daytime sleepiness using the Epworth scale also improved 3 months after the end of treatment ($p = 0.010$).

Conclusion Based on our observations, the treatment of snoring with the Er:YAG laser is an effective and non-invasive therapeutic method. Further studies with long-term follow-up and a control group are warranted to confirm the promising results obtained in the case series.

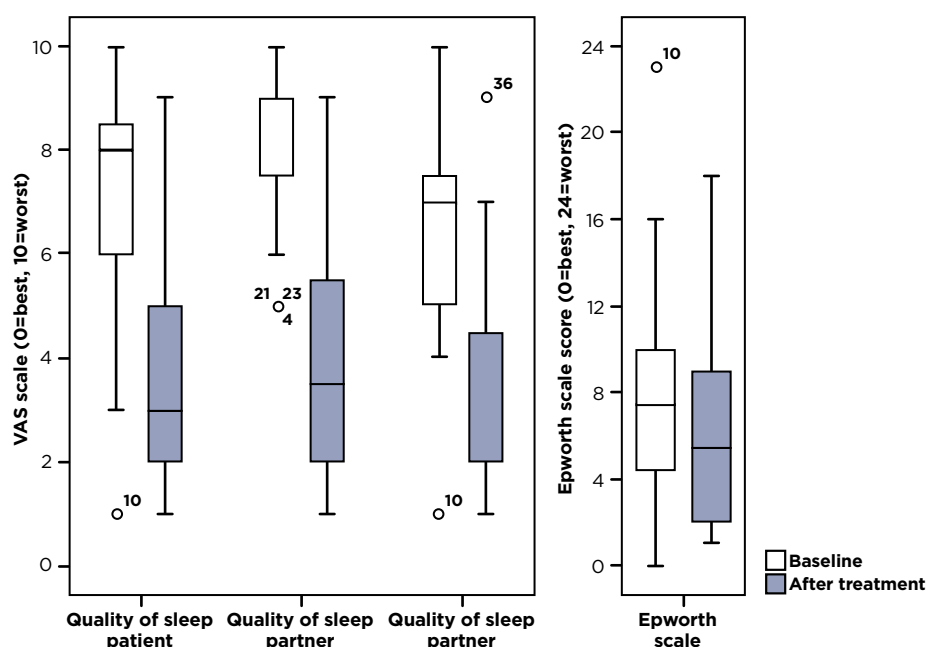


Fig. 5 Boxplot of subjective outcome measures before and 3 months after laser treatment for snoring. The boxes indicated the 1st and 3rd quartiles, and the dark lines indicated the median. Whiskers contain the full range except for points more than 1.5 times the inter-quartile range away from the box, which are shown with circles. All improvements had $p < 0.05$; however, the improvement in Epworth Sleepiness scale is not considered significant after step-wise Bonferroni correction for multiple comparisons $N=24$ for all variables.



Treatment of Snoring Disorder with a Non-Ablative Er:YAG Laser Dual Mode Protocol: An Interventional Study

Authors: L. Monteiro, A. Macedo, L. Corte-Real, F. Salazar, & J. Pacheco
 Published in: J Clin Exp Dent. 2020;12(6):e561-7. doi:10.4317/jced.56953 <https://doi.org/10.4317/jced.56953>

Background Snoring disorder is a common problem among the world's population. Treatment modalities may involve surgical and non-surgical procedures.

Objective As our main objective we proposed to evaluate the efficacy of non-ablative Er:YAG laser in the treatment of snoring disorder.

Material and Methods We performed an interventional study in 30 patients with snoring disorders. Three sessions were performed with Er:YAG laser 2940 nm in long pulse mode (2J/cm²) and SMOOTH mode (10-8J/cm²) in the oropharynx region. We analyzed the efficacy of this protocol using questionnaires for snoring intensity, snoring related characteristics of quality of life (including the Epworth sleepiness scale and OHIP-14), the satisfaction of the patients and existence of adverse effects comparing the results before and after the treatment using the Wilcoxon Signed Rank test.

Results There was a 96.7% satisfaction rate after one month of treatment, and 96.4% after 6 months. A reduction of the severity of snoring from 8±1.9 before the treatment to 1.6±1.1 one month after treatment was observed (p<0.001). Decrease in mean values of Epworth sleepiness scale (9.97±5.3 to 6.54±4.3) (p=0.002), and OHIP-14 score (10.9±6.2 to 5.9±5) (p<0.001) were also noted. A significant decrease in the Mallampati and Friedman classification scores were observed (p=0.001 and p<0.001, respectively). No anesthesia was required, nor adverse effects were observed.

Conclusion Non-ablative Er:YAG laser treatment is safe, painless, and can be an effective treatment option to reduce snoring and is well accepted by the patient. However, further controlled studies with longer follow-ups are required.

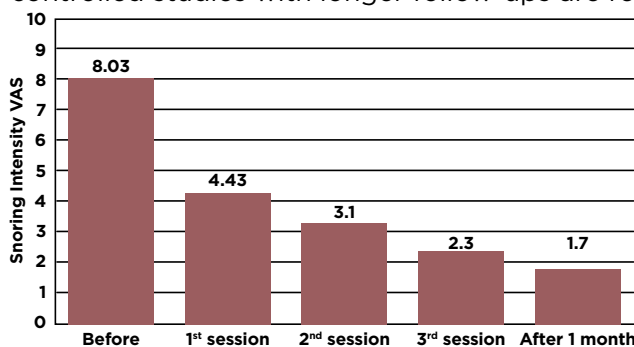


Fig. 2. Snoring VAS (snoring intensity own perception) reported before the treatment and after each treatment (TT) session and 1 month after.



Variable	Before treatment	After treatment (1 month)	P-value
Epworth sleepiness scale Mean ± S.D. Median (range)	9.97±5.3 11.5 1-18	6.54±4.3 6 0-14	0.002
Snoring VAS Mean ± S.D. Median (range)	8±1.9 8.5 (4-10)	1.6±1.1 2 (0-4)	<0.001
Dry mouth Mean ± S.D. Median (range)	6.67±3.1 5 (0-10)	0.53±1.1 0 (0-5)	<0.001
Tired during the day Mean ± S.D. Median (range)	3.4±2.4 4 (0-10)	0.10±0.4 0 (0-2)	<0.001
difficulty to wake up Mean ± S.D. Median (range)	2.7±3.2 0.5 (0-10)	0.13±0.51 0 (0-2)	<0.001
SGQ Mean ± S.D. Median (range)	26.6±11.1 28 (8-65)	2.9±2.5 2.5 (0-12)	<0.001
OHIP-14 Mean ± S.D. Median (range)	10.9±6.2 12 (1-26)	5.9±5 5 (0-15)	<0.001
Snorelab Mean ± S.D. Median (range)	47.5±17.3 22 (17-82)	30.57±18.2 31.05 (1-63)	<0.001
Mallampati scale Class I Class II Class III Class IV	1 (3.3) 9 (30) 12 (40) 8 (26.7)	6 (20) 12 (40) 9 (30) 3 (10)	<0.001
Friedman tongue position Class I Class IIa Class IIb Class IIIb Class IV	2 (6.7) 4 (13.3) 5 (16.7) 12 (40) 7 (23.3)	8 (26.7) 6 (20) 8 (26.7) 8 (26.7) 0	<0.001
Total	30	30	

S.D.-Standard deviation
 SGQ-general questionnaire score
 OHIP-14-oral health impact profile-14

Table 2. Patient's characteristics related with snoring before and after treatment.

Histological Effects of Er:YAG Laser Irradiation with Snoring Handpiece in the Rat Soft Palate

Authors: T. Unver, E. Aytugar, O. Ozturan, T. Kiran, E. Ademci, & A. Usumez

Published in: *Photomedicine and Laser Surgery*, 2016 DOI: 10.1089/pho.2015.4044

Objective The aim of this study was to assess the effects of laser irradiation with a novel snoring handpiece on the histological structures of the soft palate in a rat model.

Background Snoring is a common problem and studies have shown that 20–50% of the population is affected. An apnea–hypopnea index of < 0.05/h without daytime somnolence is documented as simple snoring. No snoring treatment should ever be attempted until a sleep study has been completed to rule out sleep apnea.

Materials and Methods Twenty adult Wistar rats, weighing 200–250g, were used in this study. Rats were randomized into two groups: an experimental group (n= 10) and control group (n= 10). Laser energy was delivered in a horizontal direction to the surface of the soft palate of each rat in the experimental group for 2 min with an Er:YAG laser (LightWalker AT; Fotona) with a snoring handpiece (PS04) in a noncontact mode (1.5 W, 2 Hz, 1.5 J/cm²). The animals were sacrificed after 24 h, 1 week, 3 weeks, or 5 weeks. The soft palate of each rat was removed by excisional biopsy. The specimens underwent histological examination. Contractions and fibrosis were reported as grading from 1+ to 3+, while edema and hyperemia were evaluated according to the absence (0) or presence (1) of any changes. Statistical analysis was done with the Mann–Whitney U and Spearman’s rho tests.

Results A noticeable contraction of the soft palate occurred immediately after laser application. Inflammatory changes were observed histologically at 3 weeks postoperatively. Keratinization appeared after the procedure in both groups and decreased gradually. Statistically, there was a strong correlation among inflammation and time and also keratinization and time ($p < 0.05$).

Conclusions The present study indicates that Er:YAG laser irradiation with a snoring handpiece (PS04) causes acute shrinkage of the mucosa. This contraction decreases gradually but is still present at the end of the fifth week.

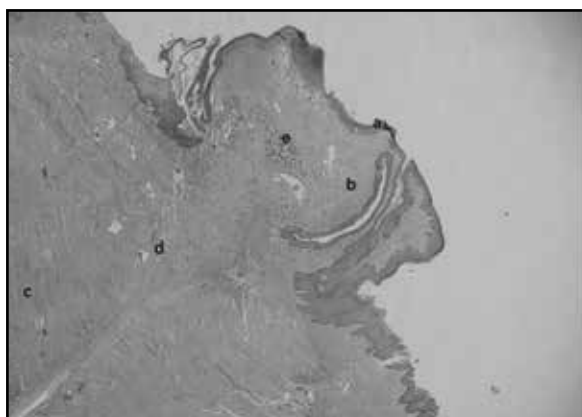


Fig 5. Acute shrinkage of the laser-irradiated soft palate (a). Mild keratinized stratified squamous epithelium (b). Subepithelial and submucosal areas (c). Muscular layer (d). Area showing contraction (e). Area showing thermal effect (H&E, x40).



Minimally-Invasive Combined Nd:YAG and Er:YAG Laser-Assisted Uvulopalatoplasty for Treatment of Obstructive Sleep Apnea

Authors: H. Shiffman, J. Khorsandi, & N. M. Caudwels

Published in: *Photobiomodulation, Photomedicine, and Laser Surgery*. 2021 doi: 10.1089/photob.2020.4947

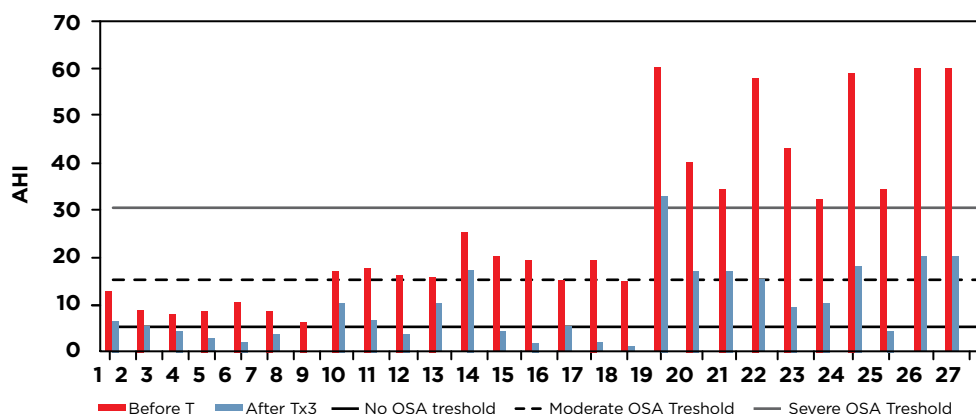
Objective In this article, the efficacy of a minimally-invasive outpatient laser-assisted uvulopalatoplasty (LAUP) procedure (NightLase LAUP) to reduce apnea-hypopnea index (AHI) in patients with obstructive sleep apnea (OSA) is evaluated.

Background OSA is a serious condition, but its treatment is often not effective or is poorly accepted by patients. Newer modes of therapy that are more effective and also more accepted by patients need to be developed. The latest treatment approaches involve a minimally-invasive LAUP procedure. This procedure involves thermal processing of the relaxed soft palate and surrounding tissues using neodymium-doped yttrium aluminum garnet (Nd:YAG) and erbium-doped yttrium aluminum garnet (Er:YAG) lasers, resulting in favorable collagen shrinkage and development of new collagen fibers. The procedure has previously been reported to safely and effectively reduce snoring, as well as increase the volume of the oropharyngeal airway, and is well accepted by patients.

Materials and methods The efficacy of the minimally invasive LAUP procedure, combining Nd:YAG laser ($k = 1064 \text{ nm}$) and Er:YAG laser ($k = 2940 \text{ nm}$) applied to the soft palate for treatment of OSA on 27 patients with different severities of OSA was evaluated based on AHI measurements before and after only three 20-min sessions in an outpatient setting over a period of 45–60 days.

Results A decrease in AHI for all the patients with different severities of OSA tested in this study was achieved, with 66.3% average improvement (32–100%). Fifty percent or more improvement was achieved in 78% (21) of all patients.

Conclusions Based on our observations, the NightLase LAUP treatment of OSA represents an effective and safe therapeutic method. Further research and longer term prospective trials are needed to improve the evidence base for the potential integration of this treatment method into the current guidelines for treatment of OSA.



G.5. AHI measurement before and after NightLase® LAUP laser treatments for 27 patients with mild (Patients No. 1-7), moderate (Patients No. 8-17), or severe (Patients No. 18-27) OSA. The complete treatment consisted of three 20-min sessions over a period of 45-60 days. Horizontal lines depict thresholds of mild, moderate, and severe OSA. AHI, apnea-hypopnea index; LAUP, laser-assisted uvulopalatoplasty; OSA, obstructive sleep apnea.



NightLase® : Minimally Invasive Laser-Assisted Uvulopalatoplasty

Authors: H. Shiffman & M. Lukac

Published in: *Journal of the Laser and Health Academy*. 2018 Vol 1, pp 39-44.

Background There are a multitude of treatment options for sleep-disordered breathing (SDB), which can be classified into conservative, apparatus and surgical methods. The choice of the method used will depend on the patient's tolerance of the procedure, and most importantly, on the severity of the patient's SDB.

Objective In this paper, 5 years of clinical experience is reported on the use of an Nd:YAG/Er:YAG dental laser system to perform the LAUP procedure to reduce symptoms of sleep-disordered breathing.

Method Using a combination of Nd:YAG (1064 nm) and Er:YAG (2940 nm) laser to treat the floor of the mouth, the soft palate, and the back of the tongue. A complete course of treatment consists of three 20-minute sessions over a course of 45-60 days.

Results The NightLase® LAUP treatment results in a visible elevation of the soft palate and uvula and tightening of the oropharyngeal tissues (Fig. 4), resulting in an improvement in the upper airway volume.

Conclusion The NightLase® LAUP therapy has a significant success rate in producing a positive change in sleep patterns.

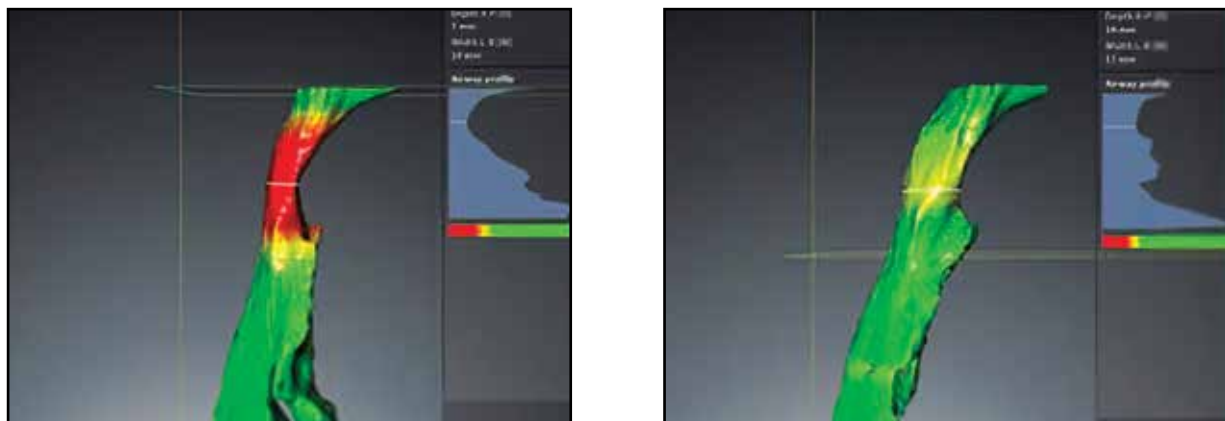


Fig. 8: Patient CBCT images taken before (left) and after (right) the treatment. The airway volume increased by 14% from 18,972 mm³ to 21,692 mm³, and the minimal cross-sectional area doubled from 76 mm² to 156 mm².



Erbium:Yttrium Aluminum Garnet (Er:YAG) Laser: A Minimally Invasive Treatment Method in Selected Patients with Impaired Breathing During Sleep—The Assessment of Treatment Effectiveness After 4 Years

Authors: H. Frelich, M. Markow, M. Tazbirek, H. Frelich-Truchel, M. Misiolek, & W. Scierski
Published in: *Photobiomodulation, Photomedicine, and Laser Surgery*. 2023 Vol 41(8), pp. 415-421.

Background Nonablative Er:YAG laser treatment has been shown to improve subjective quality of sleep without serious adverse effects, but long-term data are lacking.

Objective The aim of this study was to assess the longterm outcomes of non-ablative Er:YAG laser treatment for snoring.

Materials and methods and methods Twenty-four patients with snoring problems due to soft palate hypertrophy were treated with three treatment procedures with Er:YAG laser performed at 2-week intervals. Subjective (questionnaires) and objective (polygraph) outcome measures were assessed at baseline, 3 months, and 4 years after the final laser treatment.

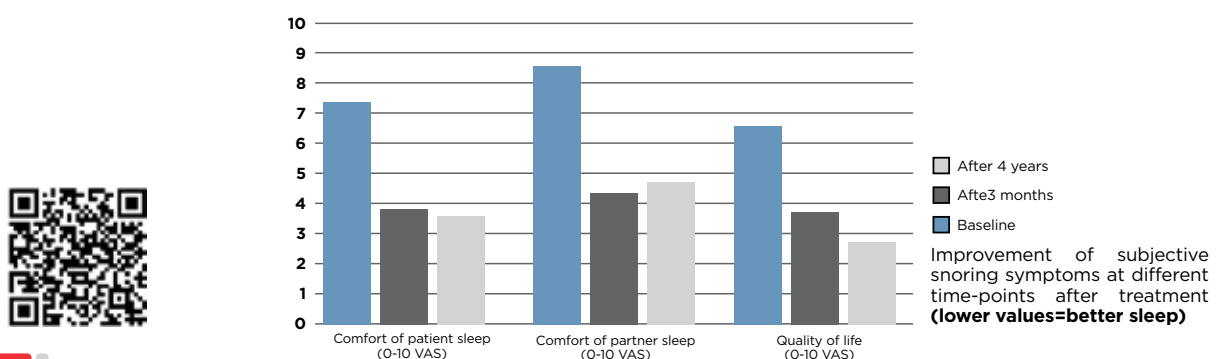
Results Twenty patients returned for the 4-year follow-up. The significant improvement in subjective sleep outcomes observed 3 months after Er:YAG laser treatment was still significant 4 years after treatment. No significant improvement or deterioration in objective polygraph outcome measures was observed during the 4 years of follow-up in our study. No side effects of laser treatment were observed.

Conclusions The Er:YAG laser treatment presents a safe and well-tolerated snoring treatment alternative for patients with airway obstruction in the oropharynx with improvement in subjective sleep outcomes lasting up to 4 years. However, there was recurrence in 34.8% of the patients who presented objective and subjective improvement of the complaints, 6 weeks postoperatively and after a 2-year follow-up period.

Variable	Baseline			3 months FU			4 years FU		
	Mean	Median	Range	Mean	Median	Range	Mean	Median	Range
Polygraph measurements									
OAI (no./h)	9.2	7.8	0.8-34	7.3	4.6	0.1-22	6.3	4.9	0-19
Hypopnea (no./h)	6.9	5.6	0.6-28	4.6	3.3	0-20	4.4	3.4	0-20
AHI (no./h)	21	21	2.5-72	16	13	2.8-48	14	15	2.5-29
Medium O2 saturation (%)	93	93	90-96	93	93	88-96	92	93	88-96
ODI (no./h)	16	12	1-60	14	10	1-56	14	12	2-42
Medium time of snoring episode (sec)	18	15	6-36	22	12	5-155	16	14	0-32
Snoring (% of sleep time)	13	11	1.7-37	12	4.8	0.1-55	8.6	5.9	0-23
Questionnaires^a									
Comfort of patient sleep (0-10 VAS)	7.2	8.0	1-9	3.8	3.5	1-9	3.7	3.0	1-8
Comfort of partner sleep (0-10 VAS)	8.5	9.0	5-10	4.3	4.5	1-9	4.6	4.5	1-8
Quality of life (0-10 VAS)	6.4	7.0	1-9	3.5	3.0	1-9	2.8	3.0	1-5
Epworth scale (0-24 score)	8.3	8.0	0-32	6.9	6.5	1-18	7.7	7.5	1-15

N=20 for all variables
^aLower values on the VAS and Epworth score indicate better sleep.
 FU, Follow-up

Table 2. Values of objective (polygraph measurements) and subjective (questionnaire) outcome measures at different time points (baseline, 3 months post-treatment, and 4 years post-treatment)



Clinical Efficacy Evaluation of Er:YAG Laser Treatments for Obstructive Sleep Apnea Hypopnea Syndrome

Authors: J. Liu, J. Yang, M. Zhang, Y. Chen, & Q. Li

Published in: Biomed J Sci & Tech Res 2019 20(3). doi: 10.26717/BJSTR.2019.20.003447

Background Obstructive sleep apnea hypopnea syndrome (OSAHS) has become an important public health concern. Although numerous treatments have been used, noninvasive and convenient methods are always desirable.

Objective This study aimed to evaluate the therapeutic effect of Er:YAG laser on OSAHS. Fifty-four mild OSAHS patients received Er:YAG laser therapy.

Methods The snoring severity and sleep quality were measured before the treatment, immediately after the 1st, 2nd and 3rd treatments, and after 3, 6 and 12 months. The patients' pain intensity, oropharyngeal feelings and satisfaction were recorded during the therapeutic period. We also measured the apnea hypopnea index (AHI), average apnea duration and percentage of saturated oxygen (SaO₂) immediately after the completion of laser therapy and 12 months of follow-up with polysomnography (PSG).

Results After Er:YAG laser therapy, the patients' snoring severity and sleep quality gradually improved over time compared with the pretreatment scores ($P < 0.05$), and they were still lower than the original state until the end of the 12 months' follow-up ($P < 0.05$). The pain score of the patients during the treatment period was low, and the oropharyngeal feelings were evidenced by throat dryness (approximately 90%) and the palatal paresthesia (12.96-20.37%). Additionally, the patients showed satisfaction with Er:YAG laser therapy. Moreover, the AHI and average apnea duration were lower after finishing the treatment and at the 12 months' follow-up than those of the pretreatment groups ($P < 0.05$).

Conclusion These results showed us the Er:YAG laser could effectively improve the symptoms of OSAHS, indicating it as a minimally invasive method for alleviating OSAHS.

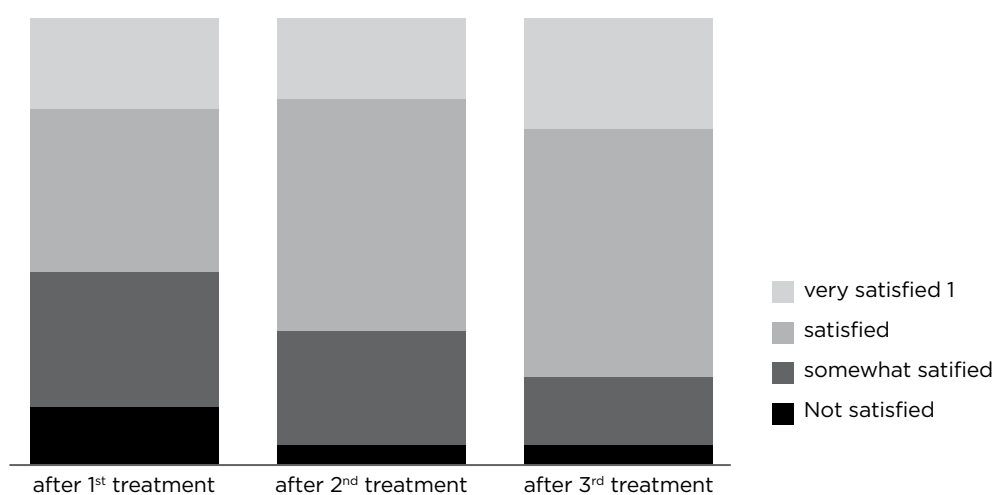


Table 2. The oropharyngeal feeling of obstructive sleep apnea hypopnea syndrome (OSAHS) patients treated with Er:YAG laser.



Combined Oral Appliance Therapy and Adjunctive Minimally Invasive Er:YAG Laser Therapy for Complete Resolution of Severe Obstructive Sleep Apnea: A Clinical Case Report

Authors: M. Bisheimer, E. Ng, M. Lagravery, & P. Mayoral

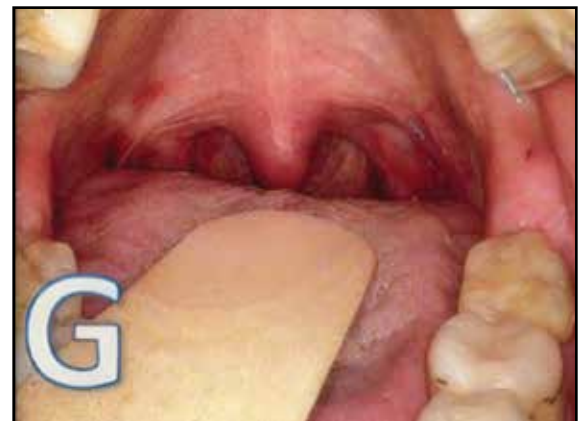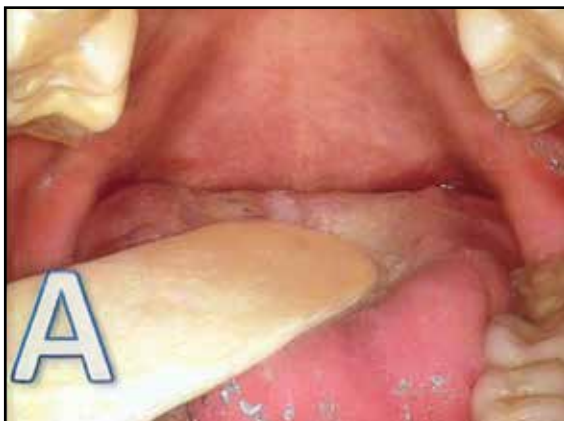Published in: *Journal of Dental Sleep Medicine*, 2023 <http://dx.doi.org/10.15331/jdsm.xx>

Objective This case report describes the use of laser therapy from an Er:YAG laser in conjunction with a custom-fit titratable dental sleep appliance for the resolution of a patient's severe obstructive sleep apnea, daytime sleepiness, snoring, and breathing sounds when sleeping.

Method A 71-year-old woman presented to a multidisciplinary sleep center with primary concerns of loud snoring with observed apneas. A custom-fit dental appliance (SomnoDent, Barcelona, Spain) was provided to the patient at a dental sleep medicine clinic with an initial mandibular position set at 50% of maximum mandibular protrusion. The patient received three sessions of NightLase and after the third laser session, the patient discontinued use of her dental sleep appliance.

Results One year later the patient underwent standard annual follow-up with a sleep study to confirm appropriately maintained management of her OSA. The results of the sleep study included an REI of 3.5 and a supine REI of 4.2.

Conclusion This case report shows the successful combined use of nonsurgical laser therapy with the transitional use of a dental sleep appliance for the resolution of severe OSA in a single patient.



Clinical photographs of the patient before and after nonsurgical laser therapy of the oropharynx following Er:YAG exposure. (A) Prior to laser therapy. (G) at one year follow up.



Er:YAG Laser Treatment of Sleep-Disordered Breathing

Authors: K. Svahnström

Published in: Journal of the Laser and Health Academy. 2013 No. 1; pp. 13-16.

Background Recently a new method (NightLase) for the treatment of snoring and obstructive sleep apnea that uses the benefits of Er:YAG laser light was presented.

Objective To test the method, the results of treatments on 75 patients with different degrees of snoring and obstructive sleep apnea were analyzed.

Method Over a two year period, 75 patients with snoring problems were treated with three sessions of Er:YAG treatment in a period of 45 days. The procedure was stopped when shrinking in the mucosa was observed. Outcome measures were Mallampati scores, visual analogue scales of pain, and questionnaires to both the patient as well as their sleep partners. Blood oxygen was also measured before and after treatment.

Results The outcome of the treatment was very beneficial for the patients and the success rate after three treatments was 90%. More than 80% of the patients also reported that they breathed much easier, being more alert and focused.

Conclusion Our clinical study confirms that NightLase treatment is an efficient method for significant snoring reduction. The treatment is quick and easy to perform, minimally invasive, doesn't require any anesthesia or post-operative therapy and has an extremely high success rate in producing a positive change in sleep patterns.

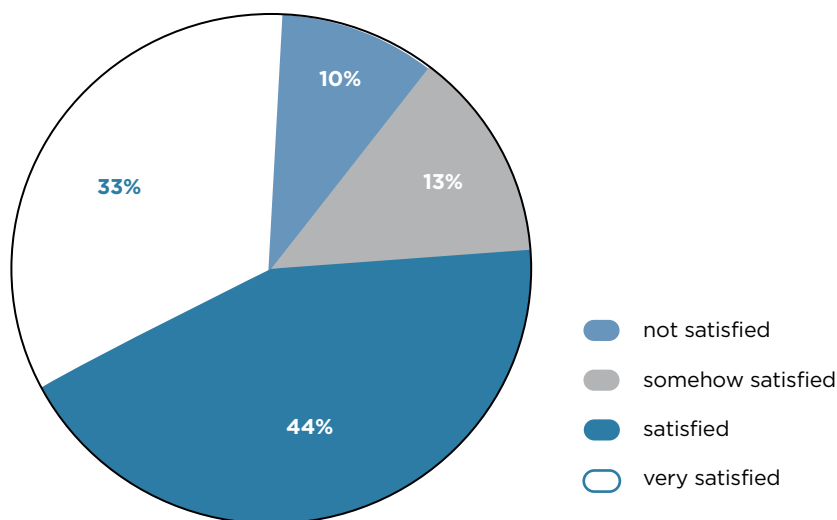


Fig. 6: Patient satisfaction with the treatment (not satisfied; somehow satisfied, satisfied; very satisfied).



Evaluation of a non-ablative Er:YAG laser procedure to increase the oropharyngeal airway volume: A pilot study

Authors: C. Lee & C. Lee

Published in: *Dental, Oral and Craniofacial Research*, 2015 doi: 10.15761/DOCR.1000113

Background Sleep disordered breathing, specifically obstructive sleep apnea (OSA) is due to constriction of the oropharyngeal airway during sleep and has major public health implications. By conservative estimates, 3% of the adult population are suffering from OSA characterized by sleep deprivation, fatigue during the day and somnolence. The most common treatment for sleep apnea is continuous positive airway pressure (CPAP). However, CPAP does not eliminate the cause of OSA.

Methods The goal of this prospective pilot study was to evaluate the changes in the total airway volume and most constricted area of the oropharyngeal airway using a non-ablative laser procedure. Cone beam computed tomography (CBCT) scans were obtained from seven patients enrolled in the study. Airway volume measurements were calculated before and after laser treatment using 3D volumetric software.

Results The photothermic effects of a non-ablative laser procedure increased the mean total airway volume from 10.23 ± 0.94 mL to 12.54 ± 1.01 mL ($p=0.0179$), and the minimum cross-sectional area from 109.7 ± 20.6 mm² to 142.4 ± 29.2 mm² ($p=0.0484$) approximately 12 weeks post-laser treatment.

Conclusions Non-ablative laser therapy may be a promising non-surgical treatment modality for increasing the oropharyngeal airway volume, especially in the most constricted area.

Clinical implications The results of this pilot study demonstrate that photothermal energy applied to the pharyngeal and palatal soft tissues may prove to be beneficial in the non-surgical management of sleep disordered breathing, especially for the CPAP intolerant individual.

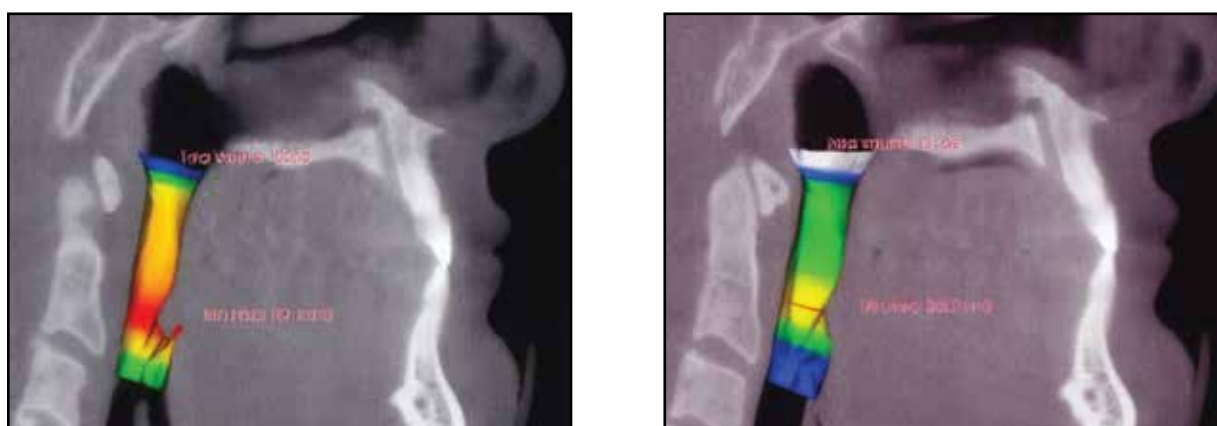


Fig. 2: Airway volume a) Before and b) After. Volumetric assessment of patient's airway using sagittal cone beam computed tomography image and anatomege's Tx Studio software before and after non-ablative laser treatment. Note the increase in both total volume and area of minimum constriction after laser treatment.



Nasal Obstruction with Hypertrophic Inferior Turbinate: Treatment with Non-ablative Erbium YAG laser – a Pilot Study with Randomized Placebo-Controlled Trial Design

Authors: P. Åhnblad

Published in: *Journal of the Laser and Health Academy*, 2017, No. 1; pp. 33-37.

Background All surgical procedures used today for the treatment of hypertrophic inferior turbinate are more or less invasive. Erbium YAG laser in non-ablative, SMOOTH thermal mode is considered as a noninvasive treatment and could be a new and safe alternative. The aim of this study was to evaluate this laser treatment*.

Objective The objectives were to evaluate the safety and performance of the laser during and after 3 sessions of treatment in one month. The primary objective was to evaluate the nasal obstruction both subjectively and objectively (by Visual Analogue Scale, VAS, and Nasal Peak Inspiratory Flow Meter, N-PIF). The secondary objective was to evaluate the nasal burden on quality of life according to a severity classification system (the modified Nasal Obstruction Symptom Evaluation Scale, or NOSE-scale).

Materials and methods 20 patients were included in this prospective, parallel group, single-blinded (patient), randomized placebo-controlled pilot study.

Results The active laser treatment showed high improvement during and after the procedure, both subjectively and objectively, regarding nasal obstruction, and decreased the nasal burden on quality of life. The placebo laser treatment showed no changes or improvements. The safety evaluation did not present any safety concerns.

Conclusion This pilot study showed that Erbium YAG laser could be an effective, rapid, non-invasive, pain free, and safe alternative method for the treatment of nasal obstruction with inferior turbinate hypertrophy. Further and larger studies with longer evaluations could be recommended for stronger evidence.

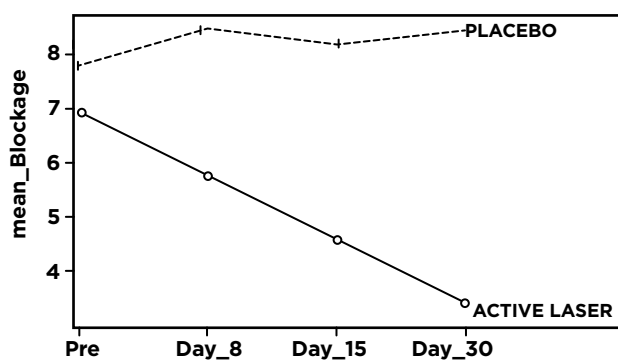


Fig. 1: The improvement for the active laser group was statistically significant with $p < 0.001$

*Not yet cleared by the FDA.



Efficacy of Low-Level Laser Therapy in Subjective Tinnitus Patients with Temporomandibular Disorders

Authors: N. Demirkol, A. Usumez, M. Demirkol, F. Sari, & C. Akcaboy

Published in: *Photomedicine and Laser Surgery*. 2017. doi: 10.1089/pho.2016.4240

Objective and background Tinnitus is an apparent sound, perceived in the ear with no stimulus. It has been described as a sound originating from the brain. It affects 17% of the general population. Etiological factors for tinnitus include temporomandibular joint disorders (TMJ, TMD) and Costen's syndrome. The aim of treatment is to eliminate the tinnitus or at least decrease its apparent volume*.

Materials and methods In total, 46 patients referred to our department with bilateral subjective tinnitus with TMDs were selected for this study. Low-level laser therapy (LLLT) with an neodymium-doped yttrium aluminum garnet (Nd:YAG) (1064 nm) laser, LLLT with a diode laser (810 nm), and placebo treatment were applied to the patients. There were 15 patients each in the Nd:YAG and placebo groups and 16 patients in the 810 nm diode laser group. LLLT was applied for 10 days, once per day. A visual analog scale (VAS) was used, with values between 0 and 10. VAS scores were recorded before treatment, on the last day of treatment, and 1 month after treatment. The VAS scores were the same on the last day of treatment and 1 month after treatment. The VAS scores before treatment and at 1 month after treatment were compared in a statistical analysis.

Results There were statistically significant differences in the Nd:YAG laser ($p = 0.001$) and 810 nm diode laser groups ($p = 0.005$), but no difference in the placebo group ($p = 0.065$).

Conclusions Both the Nd:YAG and 810 nm diode lasers were effective for the treatment of subjective tinnitus related to TMDs.

VAS SCORE (RANGE 0-10)			
GROUPS	Baseline Median (25-75%)	1 Month Median (25-75%)	P*
Nd:YAG	5 (3-5.5)	0 (0-2)	0.001*
Diode	8 (4.25-9.50)	5.5 (1.5-8)	0.005*
Placebo	6 (4-8)	5 (4-7)	0.065
p (Intergroups)	0.032*	0.001*	

*Statistically significant $p < 0.05$

Table 2. Comparison of subjective tinnitus scores on a visual analog scale at baseline and 1 month after treatment

*Not yet cleared by the FDA



Photobiomodulation Therapy for the Symptoms Related to Temporomandibular Joint Disk Displacement

Authors: P. A. Regulski, K. T. Szopinski, & S. Levičnik-Höfferle

Published in: *Case Rep Dent.* 2023 doi: 10.1155/2023/5947168

Background Pain related to temporomandibular disorders (TMD) is a common problem that can significantly influence a patient's quality of life. Laser photobiomodulation (PBM) has been reported as a promising method in medicine for wound and bone healing, pain relief, and treatment of the temporomandibular joint (TMJ).

Objective Our clinical case aimed to demonstrate the effectivity of PBM using 1064nm Nd:YAG laser for the treatment of pain and restricted mandible movement in a patient with anterior disk displacement of the left TMJ, using subjective (pain on visual analogue scale - VAS) and objective outcome measures [dynamic magnetic resonance imaging (MRI)].

Method PBM was performed on the left condyle in four sessions using a 1064nm Nd:YAG laser with a flat-top handpiece.

Results Results after 10 weeks showed an increase in mouth opening and a painless joint on palpation, with no reported adverse effects. An MRI of the TMJ confirmed the left disk displacement, however, with no signs of inflammation or effusion and with less pronounced disk deformity as compared with the first MRI examination.

Conclusion Use of PBM with Nd:YAG laser may be an efficient method for the management of orofacial pain in patients with acute and chronic TMJ disk displacements and may reduce the recovery time.



Characteristics of Piano Level Laser Therapy (PLLTM) Using Novel 1064 nm Laser Handpiece Technology

Authors: M. Lukač, Š. Levičnik Hoefflerle, S. Terlep, I. Hreljac, U. Vampelj, M. Goršič Krisper, & Z. Vižintin
Published in: Journal of the Laser and Health Academy. 2022, No. 1. ISSN 1855-9913

Background Both types of photo-biomodulation (PBM) therapy, the low-level laser therapy (LLLT) characterized by minimal temperature elevations of not more than 0.1 to 0.5°C, and as well the high-intensity laser therapy inducing temperature changes of several degrees C, are increasingly being used for the reduction of inflammation, wound healing and pain management.

Objective In this paper we report on a novel 1064 nm laser handpiece technology (MarcCoTM) that enables PLLTM (Piano Level Laser Therapy), characterized by the application of either low-level or high-level laser therapy with a stamping or brushing delivery technique.

Methods A pulsed Nd:YAG laser with a MarCo L handpiece was applied on a patient with paresis and pain in the right shoulder for 1 minute per treatment spot; 3 sessions were performed with 2-day intervals.

Results The patient had gained back full range of motion and functionality in the affected arm, and still had full range of motion six months after treatment.

Conclusion The unique capability of the MarcCoTM technology to deliver highly collimated and homogeneous beam profiles with very large spot sizes represents a significant improvement in the field of tissue stimulation.





References

- Ahnblad, P. (2017). Nasal Obstruction with Hypertrophic Inferior Turbinate: Treatment with Non-Ablative Erbium YAG Laser- A Pilot Study with Randomized Placebo-Controlled Trial Design. *J. LA&HA*, No.1; pp.33-37.
- Bisheimer, M., Ng, E., Lagravere, M., & Mayoral, P. (2023). Combined Oral Appliance Therapy and Adjunctive Minimally Invasive Er:YAG Laser Therapy for Complete Resolution of Severe Obstructive Sleep Apnea: A Clinical Case Report. *Journal of Dental Sleep Medicine*, Vol 10(1). <http://dx.doi.org/10.15331/jdsm.xx>
- Cetinkaya EA, Turker M, Kiraz K, Gulkesen HK. Er:Yag Laser Treatment of Simple Snorers in an Outpatient Setting. *ORL J Otorhinolaryngol Relat Spec*. 2016;78(2):70-6. doi: 10.1159/000443510. Epub 2016 Mar 12. PMID: 26967167.
- Demirkol, N., Usumez, A., Demirkol, M., Sari, F., & Akcaboy, C. Efficacy of Low-Level Laser Therapy in Subjective Tinnitus Patients with Temporomandibular Disorders. *Photomedicine and Laser Surgery* 2017 35:8, 427-431.
- Frelich H, Marków M, Tazbirek M, Frelich-Truchel H, Misiótek M, Scierski W. Erbium:Yttrium Aluminum Garnet (Er:YAG) Laser: A Minimally Invasive Treatment Method in Selected Patients with Impaired Breathing During Sleep-The Assessment of Treatment Effectiveness After 4 Years. *Photobiomodul Photomed Laser Surg*. 2023 Aug;41(8):415-421. doi: 10.1089/photob.2022.0144. PMID: 37579131.
- Frelich H, Scierski W, Marków M, Frelich J, Frelich H, Maciej M. Minimally invasive erbium laser treatment for selected snorers. *Lasers Med Sci*. 2019 Sep;34(7):1413-1420. doi: 10.1007/s10103-019-02731-6. Epub 2019 Feb 14. PMID: 30762193.
- Kakkar M, Malik S, Gupta B, Vaid N, George R, Singh S. Use of Laser in Sleep Disorders: A Review on Low Laser Uvulopalatoplasty. *Sleep Disord*. 2021 Feb 28;2021:8821073. doi: 10.1155/2021/8821073. PMID: 33728070; PMCID: PMC7937452.
- Kassab AN, Kharbotly AE, Elsamie AA, Ahmed MR. A Long-Term Follow-up Study for the Treatment of Snoring after Using Patterned Non-Ablative Erbium: YAG 2,940nm Laser. *Int Arch Otorhinolaryngol*. 2022 Sep 27;27(1):e104-e110. doi: 10.1055/s-0042-1744171. PMID: 36714903; PMCID: PMC9879649.
- Lee CYS, Lee CCY (2015). Evaluation of a non-ablative Er: YAG laser procedure to increase the oropharyngeal airway volume: A pilot study. *Dent Oral Craniofac Res* 1: doi: 10.15761/DOCR.1000113
- Liu, J., Yang, J., Zhang, M., Chen, Y., & Li, Q. Clinical Efficacy Evaluation of Er: YAG Laser Treatments for Obstructive Sleep Apnea Hypopnea Syndrome. *Biomed J Sci & Tech Res* 20(3)-2019. BJSTR. MS.ID.003447.
- Lukač, M., Hoefflerle, S., Terlep, S., Hreljac, I., Vampelj, U., Krisper, M., & Vižintin, Z. (2022). Characteristics of Piano Level Laser Therapy (PLLT™) Using Novel 1064 nm Laser Handpiece Technology. *Journal of the Laser and Health Academy*, No. 1. ISSN 1855-9913
- Miracki K, Vizintin Z. Nonsurgical Minimally Invasive Er : YAG Laser Snoring Treatment. *J Laser Heal Acad*. 2013;2013(1):36-41. ISSN 1855-9913.
- Monteiro L, Macedo A, Corte-Real L, Salazar F, Pacheco JJ. Treatment of snoring disorder with a non-ablative Er:YAG laser dual mode protocol. An interventional study. *J Clin Exp Dent*. 2020 Jun 1;12(6):e561-e567. doi: 10.4317/jced.56953. PMID: 32665815; PMCID: PMC7335611.
- Neruntarat C, Khuancharee K, Shoowit P. Er:YAG laser for snoring: a systemic review and meta-analysis. *Lasers Med Sci*. 2020 Aug;35(6):1231-1238. doi: 10.1007/s10103-020-02987-3. Epub 2020 Feb 28. PMID: 32112250.

Picavet, V.A., Dellian, M., Gehrking, E., Sauter, A. & Hasselbacher, K., 2022. Treatment of snoring using a non-invasive Er:YAG laser with SMOOTH mode (NightLase): a randomized controlled trial. *European archives of oto-rhino-laryngology : official journal of the European Federation of Oto-Rhino-Laryngological Societies (EUFOS) : affiliated with the German Society for Oto-Rhino-Laryngology - Head and Neck Surgery*.

Regulski PA, Szopinski KT, Levičnik-Höfferle Š. Photobiomodulation Therapy for the Symptoms Related to Temporomandibular Joint Disk Displacement. *Case Rep Dent*. 2023 Apr13;2023:5947168. doi: 10.1155/2023/5947168. PMID: 37089525; PMCID: PMC10118889.

Shiffman HS, Khorsandi J, Cauwels NM. Minimally Invasive Combined Nd:YAG and Er:YAG Laser-Assisted Uvulopalatoplasty for Treatment of Obstructive Sleep Apnea. *Photobiomodul Photomed Laser Surg*. 2021 Aug;39(8):550-557. doi: 10.1089/photob.2020.4947. Epub 2021 Feb 25. PMID: 33635143.


Shiffman, H.S., & Lukac, D.M. (2019). *NightLase: Minimally Invasive Laser-Assisted Uvulopalatoplasty*. *Journal of Laser and Health Academy*, Vol (1). ISSN 1855-9913.

Storchi IF, Parker S, Bovis F, Benedicenti S, Amaroli A. Outpatient erbium:YAG (2940 nm) laser treatment for snoring: a prospective study on 40 patients. *Lasers Med Sci*. 2018 Feb;33(2):399-406. doi: 10.1007/s10103-018-2436-6. Epub 2018 Jan 15. Erratum in: *Lasers Med Sci*. 2019 Mar;34(2):431. PMID: 29333582.

Svahnström K. Er:YAG Laser Treatment of Sleep-Disordered Breathing. *J Laser Heal Acad*. 2013;2013(2):13-16. ISSN 1855-9913.

Unver T, Aytugar E, Ozturan O, Kiran T, Ademci E, Usumez A. Histological Effects of Er:YAG Laser Irradiation with Snoring Handpiece in the Rat Soft Palate. *Photomed Laser Surg*. 2016 Aug;34(8):321-5. doi: 10.1089/pho.2015.4044. Epub 2016 May 19. PMID: 27196421.

Unver, T., Usumez, A., Aytugar, E., & Kiran, T. 2015. *Histological Effects of NightLase® in the Soft Palate of Rats: A Pilot Study*. *Journal of Laser and Health Academy*, Vol (1). ISSN 1855-9913.



Laser and Health Academy

Stegne 3
1000 Ljubljana
Slovenia, EU

www.laserandhealthacademy.com