

# Saphenous Vein Occlusion by Endovenous Laser Ablation (EVLA) with a 1064 nm VSP Nd:YAG Laser

Andrej Šikovec, MD, MSc  
*Avelana Vein Clinic, Otočec, Slovenia*

## Abstract

This paper presents a study in which **endovenous laser ablation (EVLA)** of saphenous veins with a VSP Nd:YAG laser system (Fotona, Ljubljana, Slovenia) was conducted on 525 legs. The study was held at a single clinical site (Avelana vein clinic) over a 2.5 year period. The first 102 legs underwent EVLA at 15W to 18W average power, supplied from Nd:YAG laser. In the remaining 423 legs EVLA was administered at an average power of 25W. After 1 year, 88.2% of the veins in the 15-18W treatment group remained occluded; in the 25W treatment group 98.5% of the veins remained occluded. Side effects were minimal. All patients, even those whose veins were not fully ablated reported satisfaction with the treatment. The results of the study have lead us to conclude that the 1064 nm, VSP Nd:YAG laser is an effective and safe treatment modality for varicose veins.

## Introduction

Due to higher patient satisfaction, shorter recovery times, lower cost, and ease of operation Endovenous Laser Ablation (EVLA) of the great and/or short saphenous vein has become the treatment of choice for varicose veins. EVLA shows minimal side effects in comparison with other surgical methods; patients can walk immediately after surgery and recovery times are short [1]. The EVLA procedure can be performed in an outpatient setting and usually, only local anesthesia is required.

The principle mechanism of EVLA therapy is ablation and photocoagulation of the vein interior by laser-induced thermal effects. In brief, EVLA is accomplished by inserting an optical fiber just below the saphenofemoral junction (SFJ) through the great saphenous vein (GSV) and delivering laser energy through the fiber as it is withdrawn down the GSV. During fiber withdrawal the vein wall is irreversibly destroyed and the vein is occluded. A full procedure is presented below in the Surgical Protocol section. A similar procedure can be followed for the small saphenous vein (SSV), in which the tip of the fiber is positioned at the saphenopopliteal junction.

Other superficial veins and perforators of suitable length and diameter can also be treated.

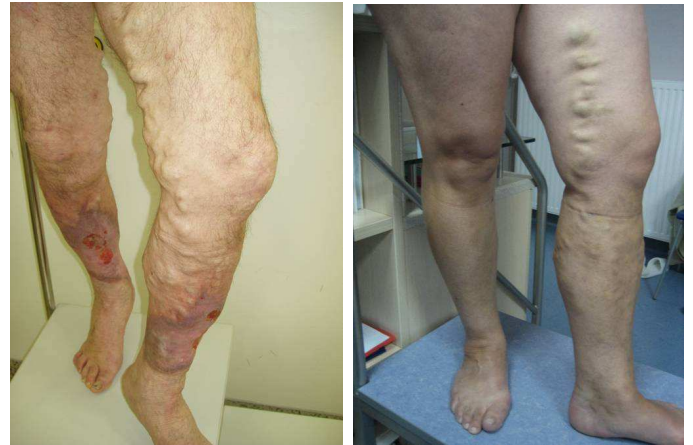

Fig. 1: Examples of severe varicosities in GSV

The primary parameters governing EVLA are the laser source wavelength, pulse form and power, and the optical fiber withdrawal rate. In this paper a multiple retrospective case study, in which EVLA was performed on 525 legs over a 2.5 year period, is presented and discussed. A 1064nm, Nd:YAG laser with Fotona Variable Square Pulse (VSP) technology was used. Two different power settings were used on two groups of patients, 15-18W and 25W.

## Wavelength Considerations in EVLA

To develop the necessary heat for effective vein wall destruction and occlusion, the target tissue must absorb laser light. Different chromophores in the target tissue absorb laser light with different efficiency at different wavelengths. For successful EVLA treatment, hemoglobin and water in the blood and vein walls must absorb laser light. Water and hemoglobin absorb well across a wide range of wavelengths and many wavelengths have been successfully used in EVLA; 810nm [1], 940nm [2,3], 980nm [1], 1064nm [5,7,9,11], 1320nm [2], and 1470 nm [10]. In the case study presented in this paper a 1064nm wavelength was used for all EVLA treatments.

Research indicates that EVLA efficacy is independent of the wavelength used [6]. However, in our

experience, more darkening (charring) of the inserted fiber-end occurs when a CW diode laser is used for EVLA, than when a pulsed, VSP Nd:YAG laser is used. Darkening of the fiber-end can change the transmission of the fiber. The transmission of the fiber should remain constant over the course of the procedure to ensure homogenous energy delivery. We tentatively attribute this observation to a “cleansing” effect of the high peak power pulses of the pulsed VSP Nd:YAG laser.

#### ***Laser Power Considerations in EVLA***

Delivering a large amount of energy in a very short time is important to the proper and efficacious administration of EVLA. In this study, laser power was the only parameter that changed between treatment groups. It was increased from 15-18W to 25W. Recent research suggests that using higher laser powers improves treatment efficacy [8]. Energy delivery is usually reported in units of joules per centimeter of the vein. This is referred to as linear endovenous energy density or LEED.

#### ***Pulse Form Considerations in EVLA***

In contrast to diode lasers, which operate continuously, Nd:YAG lasers operate in rapid pulsed mode. This means that the Nd:YAG lasers fire many times per second. Each pulse itself has a duration or period; during that period light, and therefore energy, is delivered through the optical fiber-end. In some laser systems the pulse power can vary significantly during the duration of the pulse, resulting in suboptimal energy delivery and thus reduced efficacy in vein destruction and occlusion. In this case study, the power of each Nd:YAG laser pulse was constant during the entire pulse duration, enabling well-controlled laser-tissue interaction. This was enabled by proprietary, Fotona Variable Square Pulse (VSP) technology.

#### ***Withdrawal Rate Considerations in EVLA***

The withdrawal rate of the optical fiber affects the amount of energy delivered to the vein wall. The best treatment results are achieved when the optimal amount of energy is uniformly distributed along the length of the vein. The diameter of the vein wall changes along the vein length, from 10-20mm at the SFJ to 2-3mm at the entry point, so to deliver constant energy per vein wall surface area, either the withdrawal rate or the laser energy must vary. Some manufacturers promote motorized withdrawal systems that provide a constant withdrawal rate to perform EVLA procedures. Yet these solutions cannot provide uniform energy distribution if the laser power is also held constant. Therefore most practitioners prefer to

manually control the withdrawal rate while the laser delivers constant energy; withdrawing the fiber slowly in wide sections of the vein and faster in narrow sections. Withdrawal rate was manually controlled during this study (see the Surgical Protocol section).

#### ***Surgical Protocol***

The surgical protocol [7,9] used in this study was similar to other standard protocols used for the EVLA of varicose veins [1]. All patients that participated in this study gave informed consent.

Surgery was performed according to the following steps. First, the patients were premedicated with a midazolam (Dormicum, Roche) sedative and 125 mg diklofenak (Naklofen, Krka) analgesic. Vein assessment and mapping by color-flow duplex scan was performed and a decision was made about the point of vein cannulation. The patient's leg was cleaned, draped, and a sterile operating field was prepared. A layer of gel was applied to the US probe and the probe was then covered with a watertight cover.

The patient was placed in the anti-Trendelenburg position on the table. Local intradermal anesthesia was infiltrated through a 27G needle at the point of percutaneous insertion. Care was taken so that the needle did not touch the vein. The vein was then punctured under ultrasound (US) control with a 19G needle at the selected entry point. A 0.035" J tipped guide wire was introduced into the vein. The guide was slid to the SFJ, aided by duplex monitoring, and then positioned at the SFJ. A stab incision with a blade 11 knife was made at the entry point of the guide wire. A dilator was introduced over the guide wire.

Before inserting the laser fiber and catheter assembly into the vein, the optimal laser fiber length was determined outside of the body. The laser fiber was introduced into the catheter and positioned so as to protrude 2.5cm from the distal end of the catheter. The stopper at the proximal end of the catheter was firmly tightened onto the fiber. The fiber (with properly positioned and secured stopper) was removed from the catheter. This step ensured that the fiber protrudes correctly from the catheter when the catheter is in the vein.

The dilator on the guide wire was extracted. The catheter was passed over the guide wire to the desired position at the SFJ. Once the catheter was in position the guide wire was removed, leaving the catheter inside the vein. The fiber was introduced into the

catheter and locked into its predefined position with the stopper.

Further fine adjustments were made to the catheter and fiber tip position under US control. The laser fiber was then connected to the laser system.




Fig. 2: The proper position of the fiber inside GSV, below SFJ and just below the Epigastric vein

Tumescent anaesthesia was delivered through a syringe or by special pump. When administered by syringe the anaesthetic solution consisted of 20ml of 2% lignocain (Xylocain) diluted in 100ml of saline and a 4ml of 1N solution of sodium bicarbonate. When applying anaesthesia with a special pump the anaesthetic solution consisted of 40ml of 2% lignocain (Xylocain) diluted in 500ml of saline with the addition of 8 ml of 1N solution sodium bicarbonate and 1ml of 0.1% Epinephrine.

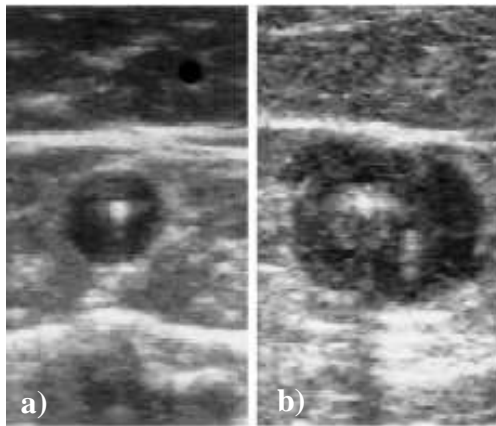


Fig. 3: The vein with catheter and fiber in the centre without (a) and with (b) tumescent anesthesia applied around it.

The laser was activated and during lasing the fiber was slowly withdrawn. The first 7 cm of extraction were US controlled. Every 10 cm the amount of delivered energy was checked. Laser energy was administered according to the generally accepted rule that LEED (J/cm) is 10x the vein diameter (mm). For the first 7 cm, energy by 50% in excess of the value indicated by

this rule was administered. The delivery of laser light was stopped 2cm from the surgical entry point.

After the laser procedure was complete micro-phlebectomies were performed to remove smaller superficial varicosities. Sutures and steri-strips were applied to the incisions. Class II medical compression stockings were given to the patients to wear for 4 weeks after the treatment.

Follow-up appointments were done 1 week, 4 weeks, 6 months and 1 year after the treatment session.

### Results

No problems were reported by any of the patients, except for mild skin irritation and ecchymosis. No deep vein thrombosis was recorded. The micro-phlebectomies usually showed transient and insignificant bruising. During follow-up appointments patients were checked with US for signs of full or partial vein recanalization. Six months after the surgery, 94% of the veins in the 15-18W treatment group and 99.2% of the veins in the 25W treatment group remained occluded. After 1 year, 88.2% of the veins in the 15-18W and 98.5% in the 25W treatment group remained occluded. All patients, even those whose veins were not fully occluded, reported being satisfied with treatment.

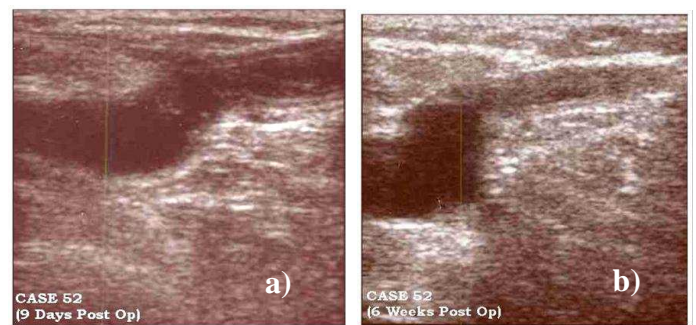


Fig. 4: Occlusion of GSV below SFJ – 9 days post-op (a) and 6 weeks post-op (b). In 6 weeks the vein is fully overgrown by surrounding tissue.

### Discussion

The Fotona's 1064nm, Nd:YAG XP-2 laser at 25W and in QCW mode is a very effective treatment modality for EVLA of the GSV and SSV varicose veins, resulting in 98.5% vein occlusion after one year. This study demonstrates that Fotona's XP-2 laser system can deliver the necessary power for the successful and safe treatment of varicose veins. After increasing the power from 18W to 25W, the percentage of occluded veins increased with 5.2% at 6 month check-up and with 10.3% at one year.

The results seen in this clinical study are in-line with results from Proebstle et al [2], who saw statistically significant differences in occlusion rate (9.7% more) between 15W and 30W at a wavelength of 940nm. Yet the same study demonstrated a statistically significant effect on side effects between three cohorts; A (940nm, 15W), B (940nm, 30W) and C (1320nm, 8W). Patients in cohort C showed less ecchymosis and felt less pain than patients in the other cohorts. Because of differences in both wavelength and power, it is difficult to directly apply these findings to treatments at 1064nm and 25W. In our study, using the same 1064nm wavelength in both patient groups, we observed no increase in side effects for procedures administered at 25W versus those at 15-18W.

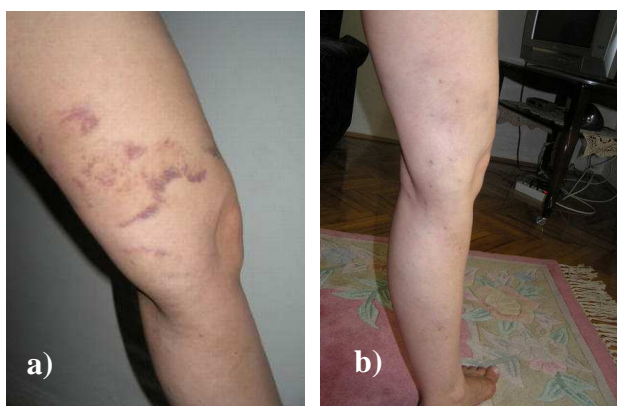

Fig. 5: Transient bruising as a side effect of micro-phlebectomies performed in the same session with EVLA at two weeks (a) and two months (b) after the procedure

Low power (15W) data for the 1064nm wavelength was published by Chang et al [5]. In this study EVLA was used to obliterate the varicose veins, although ligation was used to inhibit proximal SFJ reflux. Nevertheless the published long-term data on side effects are relevant to treatment at the 1064nm wavelength. In this retrospective multiple case study Chang et al reported on 149 patients and 252 legs, which were treated over a period of four years at one clinical center. At the six month evaluation stage, 96.8% of patients showed eradication of varices.

The most common initial side effects observed in Chang et al.'s study were ecchymosis and dyschromia in 23.0%, superficial burns in 4.8%, superficial phlebitis 1.6%, and localized hematomae in two legs 0.8%. Most of the complications resolved spontaneously with time. At the six month follow-up stage most of these minor side effects had disappeared. Local paresthesia was found in only 2.8% of legs, 0.8% still had persistent hyperpigmentation and 2.4% had minimal scarring from burn injuries. In total, 9.1% of patients still suffered from minor side

effects, 6 months after EVLA. At the 28 month follow-up, none of the patients exhibited any side effects.

The data gathered in our study and in previously published studies [2,8] supports increasing the energy dose of the laser treatment to increase the efficacy of EVLA. In agreement with other published studies [5,11], our experiences suggest that side effects are minimal when using the 1064nm wavelength. The data led us to conclude that the 1064 nm Nd:YAG laser is an effective and safe treatment modality for varicose veins.

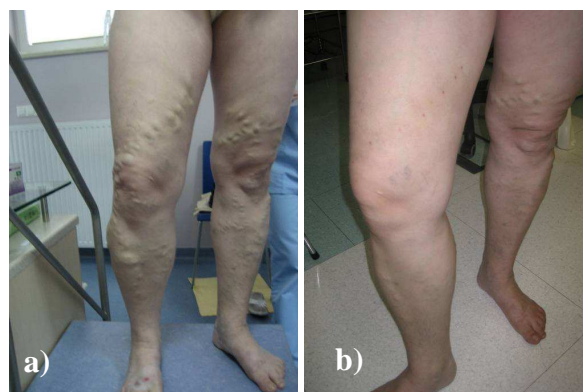

Fig. 6: EVLA provides an excellent aesthetic result – typical patient from this study, before (a) and after (b) the procedure.

#### References:

1. Agus, G. B., S. Mancini, and G. Magi. "The first 1000 cases of Italian Endovenous-laser Working Group (IEWG). Rationale, and long-term outcomes for the 1999-2003 period." *Int Angiol* 25, no. 2 (2006): 209-15.
2. Proebstle, T. M., T. Moehler, D. Gul, and S. Herdemann. "Endovenous Treatment of the Great Saphenous Vein Using a 1,320 nm Nd: YAG Laser Causes Fewer Side Effects than Using a 940 nm Diode Laser." *J. of Derma. Surg.* 31, no. 12 (2005): 1678-1684.
3. Kaudewitz, P., W. Klovekorn, and W. Rother. "Effective Treatment of Leg Vein Telangiectasia with a New 940 nm Diode Laser." *Dermatologic Surgery* 27, no. 2 (2001): 101-106.
4. Proebstle, T. M., H. A. Lehr, A. Kargl, C. Espinola-Klein, W. Rother, S. Bethge, et al. "Endovenous treatment of the greater saphenous vein with a 940-nm diode laser: Thrombotic occlusion after endoluminal thermal damage by laser-generated steam bubbles." *Journal of Vascular Surgery* 35, no. 4 (2002): 729-736.
5. Chang, C. J., and J. J. Chua. "Endovenous Laser Photocoagulation (EVLA) for Varicose Veins." *Lasers in Surgery and Medicine* 31, no. 4 (2002): 257-262.
6. Mordon, S., Wassmer, B., Zemmouri, J.: "Mathematical modeling of 980-nm and 1320-nm endovenous laser treatment", *Lasers in Surgery and Medicine* 39, No.3, Pages 256 – 265

7. Sikovec A.: »Endovenous Laser Treatment of Varicose Veins«, Ultrasound Assisted Endovenous Treatment of Varicose Vein, Avelana Otocec 2008, 55-62
8. Proebstle, T. M., T. Moehler, and S. Herdemann. "Reduced recanalization rates of the great saphenous vein after endovenous laser treatment with increased energy dosing: Definition of a threshold for the endovenous fluence equivalent." *Journal of Vascular Surgery* 44, no. 4 (2006): 834-839.
9. Sikovec A.: »Endovenous Laser treatment (ELT) with 1064 nm Nd:YAG is effective in occlusion of saphenous vein«, *Phlebologie* 4/2008, 37: A20.
10. Schwarz, T., Tschan, S., Zeller, T.: »Endovenose Lasertherapie von Varizen mit dem 1470 nm Diodenlaser – prospektive Studie«, *Phlebologie* 4/2008, 37: A21.
11. Calik M., Yavuz H. : » Will Endovenous Laser Ablation Replace The Conventional Surgery in Treatment of Varicose Veins?«, German Hospital Istanbul, paper presented on II International Symposium – New Technological Development in Health Care, Antalya, Turey, 24-27 April, 2008

### **Disclaimer:**

The intent of this Laser and Health Academy publication is to facilitate an exchange of information on the views, research results, and clinical experiences within the medical laser community. The contents of this publication are the sole responsibility of the authors and may not in any circumstances be regarded as official product information by the medical equipment manufacturers. When in doubt please check with the manufacturers whether a specific product or application has been approved or cleared to be marketed and sold in your country.