



## Treatment of Rosacea with a 6-step Protocol using the StarWalker MaQX Laser System

Dr. Carlos Bravo

### Introduction:

Many treatments have been described for this pathology, with variable results.

I present here a case successfully treated with the Fotona StarWalker MaQX laser platform, using multiple pulse modalities, combining both full spot and fractional beams and taking advantage of both the 1064 nm Nd:YAG and 532 nm KTP laser wavelengths to optimize results.

Laser	StarWalker MaQX					
	Step 1	Step 2	Step 3	Step 4	Step 5	Step 6
Wavelength	1064 nm	1064 nm	1064 nm	532 nm	532 nm	1064 nm
Handpiece	R28	R28	R28	R28	FS50B (fractional)	FS20A
Fluence	160 – 200 J/cm <sup>2</sup>	140 - 180J/cm <sup>2</sup>	2 J/cm <sup>2</sup>	1 – 1.5 J/cm <sup>2</sup>	5-15 mJ/px J/cm <sup>2</sup> until light purpura	10 mJ/px until reaching petechial bleeding
Mode	FRAC3 600 µs	VERSA	QS	QS	QS	QS
Frequency	1 Hz	0.7 Hz	10 Hz	2 Hz	3 Hz	5 Hz
Passes & Tx. area	1 pass over capillaries between 0.5 and 1 mm wide	1 pass over telangiectasias >1 mm wide (needed only in 1st session)	3 passes over entire face or until diffuse light erythema is produced	1 pass over areas with persistent erythema in cheeks and chin	1 pass over areas with erythema in cheeks and chin	1 pass over cheeks, nose and chin
Spot size	2 mm	2 mm	8 mm	6 mm	5x5 mm	9x9 mm
Sessions	3 sessions, 1 per month					



*Dr Carlos Bravo is a Costa Rican dermatologist focused on clinical, surgical and aesthetic dermatology. He is passionate for laser applications and routinely uses both long-pulse and Q-switched Fotona laser platforms in his daily practice as Medical Director of the Dermatología Integral de Costa Rica clinic. He has held positions as professor in Dermatology for several universities and is a former president of the Costa Rican Dermatology Society.*

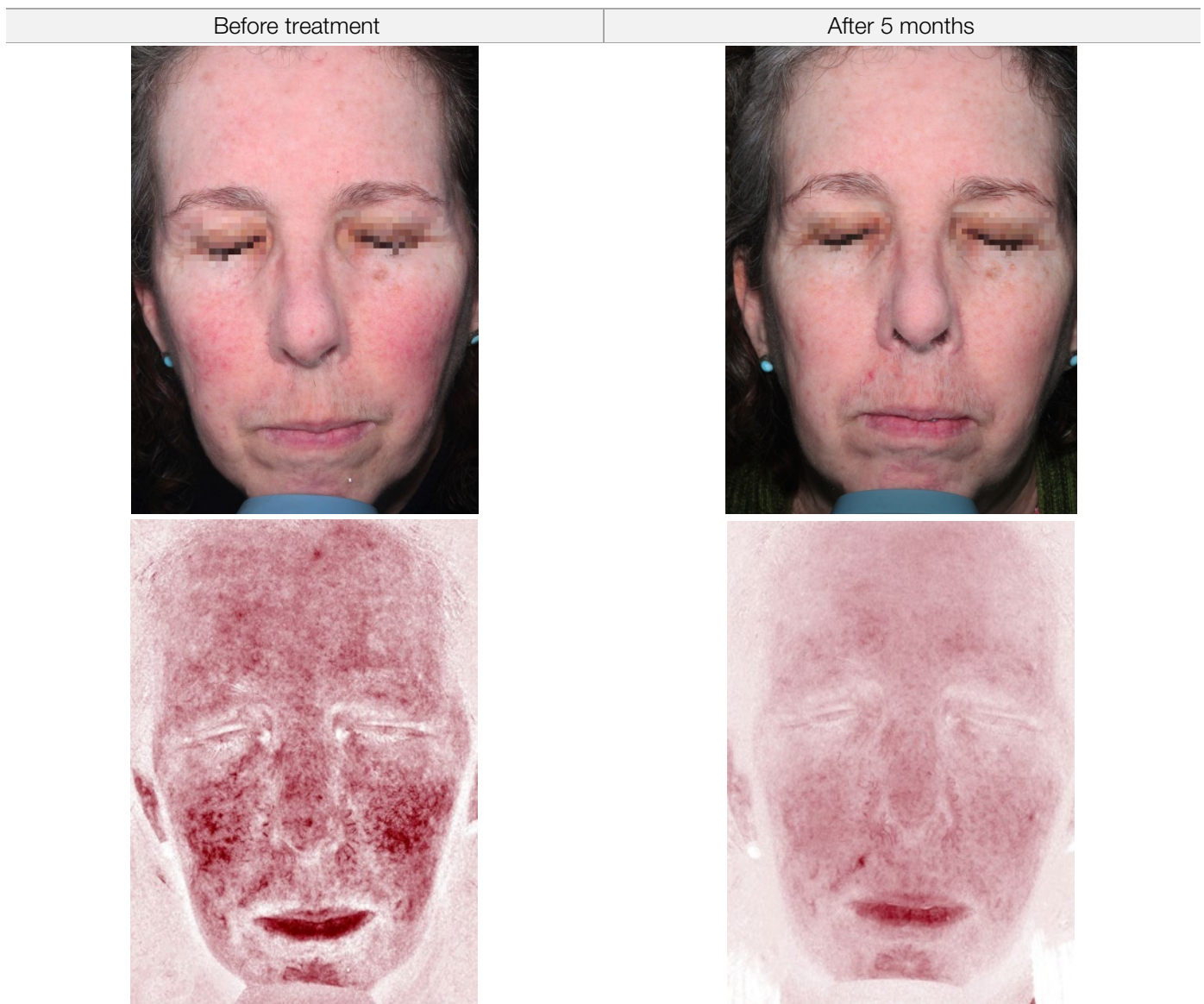
## CLINICAL CASE:

A 53-year-old female patient with Fitzpatrick phototype I, diagnosed with rosacea, with a 1-year evolution that presented intense central facial erythema and multiple telangiectasias.

Occluded triple anesthetic gel (benzocaine, tetracaine and lidocaine) was applied 1 hour prior to treatment, both for anesthetic purpose as well as for inducing vascular dilation.

1064 nm Nd:YAG in VERSA and FRAC 3 modes was used to produce photocoagulation of the telangiectasias of larger diameter. For these steps, ice compresses were used, but no cooling was applied for the rest of the treatment. Then, QS 1064 nm with full beam was applied as a photo-stimulator to reduce inflammation and improve collagen through a photoacoustic effect. Later, full-beam KTP was applied to treat superficial thin capillaries. Finally, 532 and 1064 nm lasers were used to achieve selective vascular photothermolysis in higher fluences, but with fractional beams to achieve a better effect with less risk of complications. The final result is a synergy of these different treatment modalities.

After each treatment, an intense erythema was observed, which persisted for a few hours. Punctual purpura persisted for 5 to 7 days. The patient observed clinical improvement after the first session. Currently the patient is receiving preventive sessions every 3 months with the same parameters and is being treated with sunscreen, moisturizing cream, anti-redness cleanser, metronidazole gel and azelaic acid 20%.



Published by the Laser and Health Academy. All rights reserved. © 2020

Disclaimer: The intent of this Laser and Health Academy publication is to facilitate an exchange of information on the views, research results, and clinical experiences within the medical laser community. The contents of this publication are the sole responsibility of the authors and may not in any circumstances be regarded as official product information by the medical equipment manufacturers. When in doubt please check with the manufacturers whether a specific product or application has been approved or cleared to be marketed and sold in your country.

