

ORIGINAL CONTRIBUTIONS

Non-ablative Er:YAG laser is an effective tool in the treatment arsenal of androgenetic alopecia

Doris Day MD¹  | Madison McCarthy MD¹  | Iva Talaber PhD² 

¹Doris Day M.D, New York, NY, USA

²Laser and Health Academy, Ljubljana, Slovenia

Correspondence

Iva Talaber, Laser and Health Academy, Ljubljana, Slovenia.
Email: iva.talaber@fotona.com

Funding information

No funding

Abstract

Background: Up to 70% of the adult population worldwide is affected by androgenetic alopecia (AGA) hair loss. Laser therapy offers an addition or alternative to pharmaceutical and surgical treatment of hair regrowth, with non-ablative lasers being preferred over ablative lasers in terms of safety and downtime. Combining laser therapy with different topical agents may result in better hair regrowth.

Objective: The aim was to evaluate the effectiveness and safety of non-ablative Er:YAG laser used in clinical practice, alone or in combination with other treatment modalities, in patients with both early and advanced stages of AGA.

Methods and patients: Sixteen patients (7 male and 9 female) with active AGA in different stages were treated with the non-ablative Er:YAG laser (SMOOTH™ mode, 7 mm spot size, 7.00 J/cm² pulse fluence, 3.3 Hz frequency) as a monotherapy or in combination with injections of platelet-rich plasma (PRP) to the scalp, topical minoxidil, and oral supplements for the promotion and support of hair growth. Efficacy was assessed with clinical assessment of AGA grade (Ludwig scale for female / Norwood-Hamilton scale for male) and with blind evaluation of hair quality in global photographs before and after treatment. Patients subjectively rated their satisfaction with the laser treatment on a scale from 0–3 and pain on a VAS scale from 0–10.

Results: AGA grade after treatment was lower compared to baseline ($p = 0.015$ and $p = 0.125$ in female and male patients, respectively). Blind evaluation indicated an improvement in hair quality in 93% of patients, either being described as much better (14%) or as better (79%), which was not correlated with age or AGA grade. The median satisfaction score was 3, and the median VAS score for pain was 2. The positive effect of the treatment on the hair quality is ongoing. No adverse reactions were reported.

Conclusions: The treatment was effective in treating AGA, confirmed by a decrease in AGA grade and by blinded evaluation of global photographs. Although the possible additive or complementary effect of topical minoxidil or nutraceuticals cannot be excluded, our results suggest that the non-ablative Er:YAG laser SMOOTH™ mode as a monotherapy, or in combination with PRP, is an efficient and safe treatment for AGA—with a high satisfaction rate among patients regardless of patient age, AGA duration, or AGA stage.

[Correction added on September 11, 2021 after first online publication: Text from the Results section was mistakenly placed in the Figure 1 legend. It has now been corrected]

This is an open access article under the terms of the Creative Commons Attribution-NonCommercial License, which permits use, distribution and reproduction in any medium, provided the original work is properly cited and is not used for commercial purposes.

© 2021 The Authors. *Journal of Cosmetic Dermatology* published by Wiley Periodicals LLC.

KEYWORDS

androgenetic alopecia, combined therapy, hair restoration, laser therapy, platelet-rich plasma

1 | INTRODUCTION

Androgenetic alopecia (AGA) is the most common hair loss disorder, affecting up to 70% of the adult population worldwide, with prevalence increasing with age in both genders.¹ It is estimated to affect 50% of males and females by the age of 50 and 80, respectively.² AGA can have a profoundly negative impact on quality of life,^{3,4} with early-age onset of AGA being especially important as a possible source of depression in young adults.⁵ It is characterized by progressive and gradual miniaturization of hair follicles, accompanied by progressive decrease in the duration of anagen and reduction of anagen to telogen ratio.⁵

In the last decade, laser therapy has established itself as an important alternative to the pharmaceutical (ie., finasteride and minoxidil) and surgical (ie., hair transplantation) treatment of AGA, with several studies demonstrating its efficacy in absence of adverse effects.^{6,7} Although low-level laser therapy utilizes photobiomodulation mechanisms to induce cellular metabolism,⁸ high-energy medical lasers can produce enough energy to induce tissue regeneration through photo-thermal effects. Studies on murine models suggest that fractional laser irradiation affects the hair cycle by promoting telogen to anagen transitions,⁹ in both the non-ablative 1550 nm erbium-glass⁹ and ablative 2940 nm erbium-YAG,¹⁰ as well as ablative 10 600 nm CO₂ laser.¹¹ Another proposed mechanism is laser-induced increased blood flow at the dermal papilla.¹² Effective hair growth stimulation in AGA patients with non-ablative fractional laser treatments has already been reported.^{13,14}

Several studies have reported that combining laser therapy with different topical agents results in better hair regrowth.¹⁵⁻¹⁸ One study using non-ablative 1927-nm fractionated thulium laser treatment reported a greater increase in hair density and thickness when combined with post-laser treatment application of a growth factor solution.¹³ The role of growth factors contained in platelet-rich plasma (PRP) in hair growth has been recently highlighted.^{19,20} PRP is an autologous serum harvested from venous blood, which contains high concentrations of platelets and growth factors.²¹ The anti-apoptotic effect of growth factors contained in PRP has been suggested as one of the most important factors stimulating hair growth, improving the survival of dermal papilla cells during the hair cycle.²² Combining PRP injections with other hair restoration treatments may enhance the overall efficacy.²¹

In this study, a novel laser modality was used to treat AGA—non-ablative Er:YAG treatment using a SMOOTH™ mode, consisting of trains of sub-ablative laser pulses. The advantage of Er:YAG laser used in SMOOTH™ mode is that laser light is absorbed in the most superficial (<10 μm) layer of the skin, with only heat diffusing to the deeper layers, making it a very safe form of energy, which is especially important when treating the scalp. The heat pulses penetrate the skin to approximately 0.5 mm in depth, resulting in paracrine

signaling that activates fibroblasts to initiate regenerative processes in the skin.^{23,24}

The aim of this retrospective clinical study was to assess the effectiveness of the novel non-ablative Er:YAG laser treatment, either as a monotherapy or in combination with subcutaneous injections of PRP to the scalp.

2 | METHODS AND PATIENTS

This study was a retrospective cohort clinical study for AGA outpatients from Doris Day M.D.P.C., including all patients that have received either non-ablative laser treatment alone or in combination with PRP injections in our clinic in the interval from January 2019 to January 2020. A full scalp examination for pattern and stage of androgenic alopecia was performed for every patient at baseline (ie, before the start of the treatment). The total number of androgenic alopecia patients in the present study was 16 (9 women and 7 men). All patients had active AGA. The AGA grade was assessed with the Norwood-Hamilton (1-7) classification for male and the Ludwig (1-3) classification for female patients. Detailed information on patient demographics and AGA diagnosis is presented in Table 1. Prior to the start of this study, 11 patients have been using topical minoxidil (5% or 6%) and oral nutraceuticals (Nutrafol (Nutraceutical Wellness Inc) and Viviscal (Viviscal®)) for a period of 1-3 years and have not seen the desired effect and sought additional treatment. They mostly continued with minoxidil and nutraceutical use throughout the period of this study; however, patient compliance with these adjunctive therapies was not directly monitored as closely, as patients completed these at home and not in the office. All patients who had combination therapy started laser treatments after 6 months or longer on the other protocols. All patients signed the informed consent form after understanding the nature of the trial.

All patients received 8 treatment sessions with the 2940 nm non-ablative Er:YAG laser (SP Dynamis, Fotona, Slovenia) with SMOOTH™ mode at 2-week intervals using fixed parameters (7 mm spot size, 7.00 J/cm² pulse fluence, 3.3 Hz frequency). The laser handpiece was moved in a cross-hatched pattern across the scalp for 4 passes, and the total amount of energy delivered on average was 450J. The total area of alopecia was treated. In 10 out of 16 patients (Table 1), treatment was combined with PRP at every other session (4 sessions in total). Two different kits for obtaining PRP were used: the Eclipse PRP Kit (Eclipse MED) and the ProGen PRP Kit (Crown Laboratories, Inc.). With the Eclipse PRP, the patient's blood was drawn using a 22 ml collection tube and centrifuged at 3785 g for 10 min. With the ProGen PRP Kit, the patient's blood was drawn using a 60-mL collection tube containing 9 ml of anticoagulant ACD-A and centrifuged at 4025 g consecutively 3 times: for 4 minutes, for 1 min, and 8 min. In both cases, with the Eclipse PRP Kit and the ProGen PRP

TABLE 1 Information on patient demographics and AGA condition

Patient number	Gender	Age	Duration of AGA (years)	AGA grade before treatment ¹	AGA Scalp region(s)*	Treatment modality
1	F	21	2	2 Ludwig	M, V	Laser *
2	F	67	2	2 Ludwig	V, F, M	Laser *
3	M	41	6	2 N-H	TL, TR, V	Laser *
4	M	23	4	2 N-H	TL, TR, M, V	Laser *
5	M	58	1	6 N-H	F, M, V, TL, TR	Laser *
6	M	61	13	6 N-H	F, M, V, TL, TR	Laser
7	F	32	8	3 Ludwig	F, M, V, TL, TR	Laser + PRP ^b
8	F	57	18	1 Ludwig	M, V	Laser + PRP ^b *
9	F	59	9	2 Ludwig	M, V	Laser + PRP ^b
10	F	51	2	2 Ludwig	F, M, V	Laser + PRP ^a *
11	F	54	3	1 Ludwig	TL, TR	Laser + PRP ^a *
12	F	74	3	2 Ludwig	TL, TR, M, V	Laser + PRP ^a *
13	F	61	3	2 Ludwig	TL, TR, M	Laser + PRP ^a *
14	M	45	5	3 N-H	TL, TR, V	Laser + PRP ^a *
15	M	62	21	3 N-H	TL, TR, M, V	Laser + PRP ^a
16	M	42	3	4 N-H	F, M, V, TL, TR	Laser + PRP ^b

¹AGA grade is assessed with the Ludwig scale in female patients and with the Northwood-Hamilton (N-H) scale in male patients. AGA grade scalp regions: F-frontal, M-midscalp, V-vertex (crown), TL-temporal left, TR-temporal right. PRP^a—extraction with Eclipse PRP Kit, PRP^b—extraction with ProGen PRP Kit. *Prior and concomitant use of topical minoxidil and oral nutraceuticals.

Kit, the extracted PRP was distributed into separate 3-mL syringes containing 0.15 cc of lidocaine each. In the following, we refer to the PRP extracted with the Eclipse PRP and the ProGen Kit as PRP^a and PRP^b, respectively. The prepared PRP solution was then injected in 0.1–0.2 cc aliquots subcutaneously into the patients' scalp with a 30G needle, starting at the frontal hairline and moving posteriorly at 1 cm increments.

Global photographs were taken before the first and after 8 sessions, representing before and after picture, respectively. The patients were examined for potential adverse effects during treatment and at subsequent follow-up appointments at 3, 6, and 12 months after treatment. All patients included in this study decided to continue with the treatment in the form of maintenance sessions at least once every 3 months.

Subjective (patient satisfaction questionnaire, VAS scale for pain) and objective (clinical evaluation and blind evaluation) tools were used to assess the efficacy of treatment. Patient satisfaction was measured on a 4-point scale (0-not satisfied, 1-somewhat satisfied, 2-satisfied, 3-very satisfied). The level of treatment discomfort was assessed by the patients after each treatment session on the VAS scale 0–10 (0 = no pain, 10 = worst possible pain). The clinical evaluation of the treatment outcome was designated as *improved* if the AGA grade decreased after treatment or as *no change* if there was no observed change in the AGA grade after the treatment. Blind evaluation of the treatment outcome was conducted by 7 evaluators. The evaluators received a picture composed of 2 plates, representing global photographs of hair quality before and after treatment in random order, so the evaluators were unaware of which of the pair of photographs was taken before and after treatment. They were

asked to choose a score from the following options: (–2) hair quality on the left plate is *much better* compared to right plate, (–1) hair quality on the left is *better* compared to the right plate, (0) *no difference* in hair quality between the left and right plate, (+1) hair quality on the right is *better* compared to the left plate, and (+2) hair quality on the right is *much better* compared to the left plate. After the blind evaluation was completed, the collected scores were assigned to a 5 point evaluation scale as follows; (–2) much worse, (–1) worse, (0) no difference, (+1) better, and (+2) much better. The median score of the seven raters was taken as the final blind evaluation score.

Statistical analysis was performed in Microsoft Excel and GraphPad Prism. Data were checked for normality. As normality was not met, non-parametric test was used. To analyze differences between different treatment modalities, nominal data were arranged in binary contingency tables and the Fisher exact test was used to assess statistical significance. Wilcoxon matched pairs signed rank test was used to compare AGA grade before and after treatment. Due to differences in scales used for female and male patients (Ludwig and North-Hamilton scale, respectively), the change in AGA grade in female and male patients was assessed separately. Correlation between independent variables was calculated with the Spearman correlation coefficient (rho). The chosen level of statistical significance (alpha) was 0.05.

3 | RESULTS

The mean age of the population was 50.5 years (range: 23–74 years). The mean duration of AGA in patients was 6.4 years (range:

1–18 years). Patient age and AGA duration were not significantly correlated ($\rho = 0.08, p = 0.76$).

We assessed the potential difference in treatment outcome between groups receiving different modalities. First, we assessed differences between groups Laser + PRP^a and Laser + PRP^b. There were no statistically significant differences between the groups as determined by the Fisher exact test in any of the metrics (Table 2). In the next step, the patients from groups Laser + PRP^a and Laser + PRP^b were grouped together (Laser + PRP) and compared with Laser group (Table 3). No difference in treatment outcomes between groups was detected.

On average, the patients from Laser group were younger compared to the patients from Laser + PRP group and had AGA for less time, although the differences were not statistically significant according to the Mann-Whitney test either in age (average (laser) = 45.2 years, average (laser + PRP) = 53.7 years, $U = 23.5, p = 0.51$), or AGA duration (average (laser) = 4.7 years, average years (laser + PRP) = 7.5, $U = 20, p = 0.29$).

As no differences in the study metrics between treatment modalities (laser + PRP^a and laser + PRP^b or laser and laser + PRP) were detected, analyses were performed on a pooled sample of all patients.

Using the 4-point scale previously described, patients scored their satisfaction with the overall treatment outcome. Three patients (19%) rated their satisfaction with a score of 2 and 13 patients (81%) with a score of 3. The median satisfaction was 3. No significant correlation was detected with age ($\rho = 0.16, p = 0.56$) or the blind evaluation score ($\rho = 0.09, p = 0.73$), and no significant difference between female (mean = 2.9, $n = 9$) and male (mean = 2.7, $n = 7$) gender was detected ($U = 26, p = 0.55$).

A decrease in AGA grade after treatment was detected in 11 out of 16 patients (64%). In female patients, the AGA grades before (mean = 1.89, $n = 9$) and after (mean = 1.11, $n = 9$) treatment were significantly different ($W = -28, p = 0.015$). In male patients, the AGA grades before (mean = 3.71, $n = 7$) and after (mean = 3.14, $n = 7$) treatment were not significantly different ($W = -10, p = 0.125$). Clinical evaluation (improved/no change in AGA grade) was not

TABLE 2 Comparative assessment of outcomes between groups receiving PRP injections, obtained with different kits

	Laser + PRP ^a (n = 6)	Laser + PRP ^b (n = 4)	Fisher's exact test
Patients' satisfaction			
Very satisfied	6	3	$p = 0.40$ ns
Satisfied	0	1	
Blind evaluation			
Much better/Better	1	0	$p > 0.99$ ns
No change	5	4	
Clinicalevaluation			
Improved	4	2	$p > 0.99$ ns
No change	2	2	

significantly correlated with age ($\rho = 0.37, p = 0.14$) or AGA duration ($\rho = -0.13, p = 0.62$) or blind evaluation ($\rho = 0.44, p = 0.06$).

Blind evaluation of treatment outcome ranged from 0 (no difference) to +2 (much better), with the majority of scores registering 1 (better). Only 1 patient (6%) received a median score of 0 (no difference), 12 patients (75%) received a median score of 1 (better), and 3 patients (19%) received a median score of 2 (much better). No significant difference ($U = 30, p = 0.76$) was detected between female (mean = 1.10, $n = 9$) and male (mean = 1.14, $n = 7$) gender. Blind evaluation scores were not significantly correlated with age ($\rho = 0.15, p = 0.58$) or AGA duration ($\rho = -0.17, p = 0.51$).

4 | DISCUSSION

This was a retrospective cohort study, which aimed to evaluate the effectiveness of the non-ablative Er:YAG laser as a monotherapy or in combination with PRP injections and topical treatments for the treatment of AGA. We have found that the laser treatment was

TABLE 3 Comparative assessment of outcomes between groups receiving laser as monotherapy and laser combined with PRP

	Laser (n = 6)	Laser + PRP (n = 10)	Fisher's exact test
Patients' satisfaction			
Very satisfied	4	9	$p = 0.52$ ns
Satisfied	2	1	
Blind evaluation			
Much better/Better	5	10	$p = 0.38$ ns
No change	1	0	
Clinical evaluation			
Improved	5	6	$p = 0.59$ ns
No change	1	4	

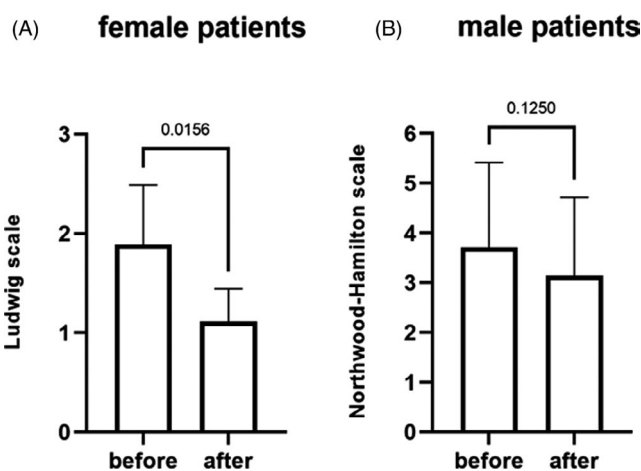


FIGURE 1 Difference in AGA grade (mean \pm SD) before and after the treatment in (A) female patients ($n = 9$) and (B) male patients ($n = 7$). The numbers above the charts represent p -values for Wilcoxon matched pairs test

TABLE 4 Results of the subjective and objective assessment of treatment

Patient number	AGA after treatment ¹	Patients' satisfaction	Blind evaluation	Clinical evaluation	Treatment modality
1	1 Ludwig	Very satisfied	Much better	Improved	Laser *
2	1 Ludwig	Very satisfied	Better	Improved	Laser *
3	1 N-H	Very satisfied	Better	Improved	Laser *
4	2 N-H	Satisfied	No Change	No Change	Laser *
5	5 N-H	Satisfied	Much Better	Improved	Laser *
6	5 N-H	Very satisfied	Better	Improved	Laser
7	2 Ludwig	Very satisfied	Better	Improved	Laser, PRP ^b
8	1 Ludwig	Satisfied	Better	No Change	Laser + PRP ^b *
9	1 Ludwig	Very satisfied	Better	Improved	Laser + PRP ^b
10	1 Ludwig	Very satisfied	Better	Improved	Laser + PRP ^a *
11	1 Ludwig	Very satisfied	Better	No change	Laser + PRP ^a *
12	1 Ludwig	Very satisfied	Better	Improved	Laser + PRP ^a *
13	1 Ludwig	Very satisfied	Better	Improved	Laser + PRP ^a *
14	3 N-H	Very satisfied	Better	No change	Laser + PRP ^a *
15	2 N-H	Very satisfied	Much better	Improved	Laser + PRP ^a
16	4 N-H	Very satisfied	Better	No change	Laser + PRP ^b

¹AGA grade is assessed with the Ludwig scale in female patients and with the Northwood-Hamilton (N-H) scale in male patients. PRP^a—extraction with Eclipse PRP Kit, PRP^b—extraction with ProGen PRP Kit. *Prior and concomitant use of topical minoxidil.

effective both when used alone or in consequent combination with PRP injections, as demonstrated by the decrease in AGA grade. No significant differences between the two treatment modalities were detected in any of the study metrics; hence, no distinction has been made between the two in the following discussion. Nevertheless, the presumed contributing effect of the PRP therapy to the laser treatment might be obscured in this study, in part due to the study design and sample size, but also due to differences in patient demographics and AGA duration (Table 1), as patients that received laser monotherapy were younger on average and had AGA for less time. It has to be noted that 11/16 patients have also been administering topical minoxidil and oral nutraceuticals up to 3 years prior to and during the study. As they have not experienced the desired effect on their AGA condition, they started with the treatment described in present study. Topical minoxidil and oral nutraceuticals treatments were self-administered with possibly variable compliance; therefore, we could not quantify their possible additive or complementary effects. Nevertheless, a contributing effect may be anticipated as several studies reported beneficial effects of combining different treatment modalities. For example, combination of topical minoxidil and low level¹⁵ or fractional laser²⁵ therapy has been reported to be more effective than either therapy alone, and similarly, combination of PRP therapy and topical minoxidil was found to be more effective than minoxidil alone.²⁶

The improvement in AGA condition presumably depends on stimulation of the hair cycle. It may be speculated that a synergistic effect of different modalities results in better treatment outcomes. Hair follicles are stem cell-rich systems that repetitively regenerate in continuous cycles consisting of three stages: growth (anagen),

involution (catagen), and rest (telogen), all of which are largely affected by the Wnt/ β -catenin signaling pathway.²⁷ The dermal papilla of the hair follicle is the major regulator of numerous processes in the hair cycle including progenitor cell activation.²⁷ Interestingly, the up-regulation of the Wnt/ β -catenin signaling pathway to stimulate hair growth has been indicated in both PRP^{22,28} and laser treatment.^{10,27}

Overall, the treatment resulted in considerable improvement, as AGA grades decreased in 69% of all patients. Some studies have reported better results of hair restoration treatments in patients with lower AGA grades, both in the case of laser²⁹ and PRP treatment.^{30,31} In contrast, in our study a decrease in AGA grade (Figure 1, Table 4) was detected regardless of AGA grade at baseline, patient age, or AGA duration (Figure 2). This is a positive finding which indicates that patients with a more advanced AGA can benefit from this type of hair regrowth treatment as well. Accordingly, the results of blind evaluation (Figure 3) indicated improvement in hair quality in 93% of patients, either being described as much better (15%) or as better (85%), which was not correlated with age or AGA grade. Only in 1 patient, representing 6% of all patients, have the blinded evaluators seen no difference in hair quality before and after the treatment. The subjective assessment of the treatment via the patient satisfaction score demonstrates the high level of satisfaction among patients (Figure 4). 79% of patients described their satisfaction with the highest score on a scale from 0–3. It has to be noted that in order for patients suffering from long-term AGA to express this level of satisfaction, they must experience significantly decreased shedding, increased growth and retention of hair.

In a set of 16 patients, no adverse effects were reported, either during treatment, after the treatment was completed, or at

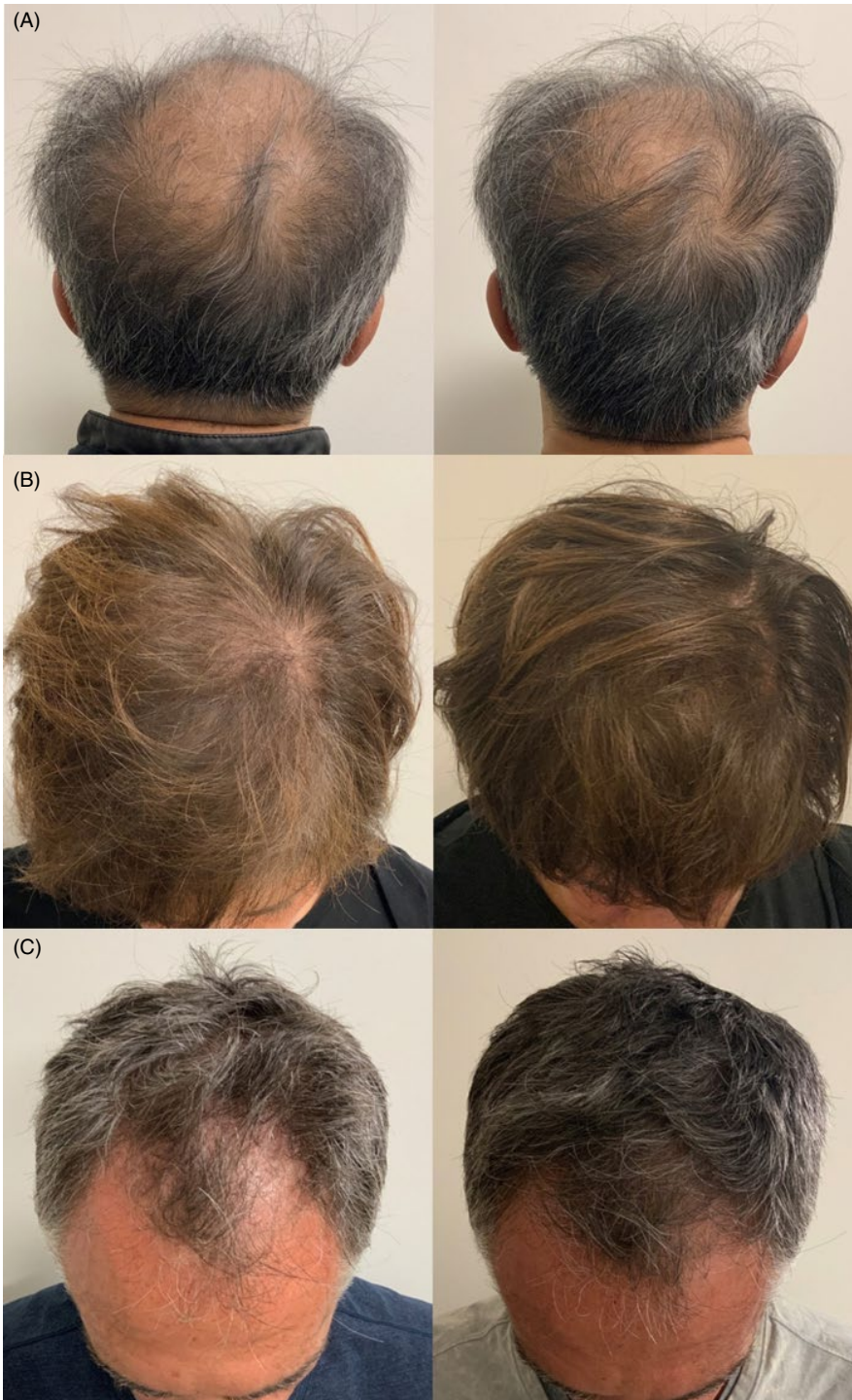


FIGURE 2 Representative before and after photographs of three patients. (A) Patient 6, treated with laser monotherapy. AGA stage improved from N-H stage 6 to 5 (North-Hamilton stage), and hair quality was assessed as better by blind evaluation after treatment; (B) patient 9, treated with laser combined with PRPb. AGA stage improved from grade 2 to 1 (Ludwig scale), and hair quality was assessed as better by blind evaluation after treatment; (C) patient 15, treated with laser combined with PRPa. AGA stage improved from N-H stage 3 to 2, and hair quality was assessed as much better by blind evaluation after treatment

subsequent follow-up visits (3, 6, and 12 months). Pain during treatment was assessed by patients uniformly as at level 2 on the VAS scale (0–10). The results of this study corroborate the results of a case study where a combined treatment with the non-ablative Er:YAG laser combined with subcutaneous injections of PRP gave significant results in treating androgenetic alopecia in one male patient, with long-term preservation of the achieved results.³² The patients treated in this study are continuing with a maintenance treatment once every 3 months, and the duration of the positive effect is ongoing. The effectiveness of a similar treatment protocol

was reported in another recent study,³³ where significant improvement in hair quality was detected in 92% of patients receiving non-ablative Er:YAG laser monotherapy and in 100% of patients receiving a combined therapy with post-laser application of growth factors.

5 | CONCLUSION

Hair loss is associated with great emotional distress. The treatment employed in this study provided relief and renewed hope for many

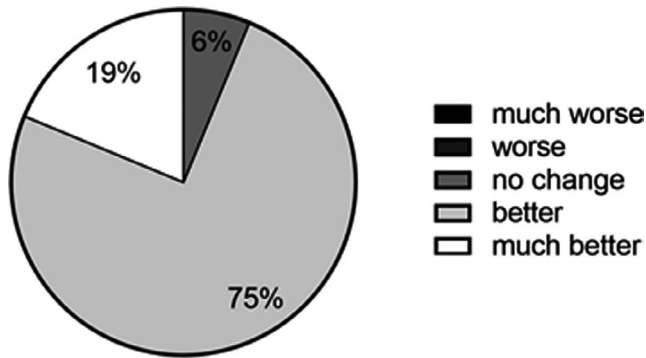


FIGURE 3 Hair quality after treatment as assessed by the blind evaluation of global photographs

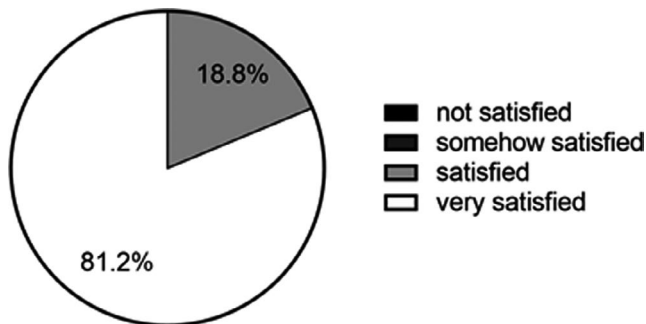


FIGURE 4 Patient satisfaction

of the patients, who have struggled with the AGA condition for many years. The effectiveness of treatment was demonstrated by a decrease in AGA grade and the blind evaluation, where hair quality after treatment was rated better or much better in 94% of patients. The patients were generally very satisfied with the outcome. No adverse effects were reported by patients during the study or at follow-up appointments at 3, 6, and 12 months. The duration of the positive effect is ongoing. The study design and sample size of this study do not support conclusions regarding the effect of each treatment modality used. Nevertheless, the results suggest non-ablative Er:YAG laser in SMOOTH™ mode as a monotherapy or in combination with PRP, topical minoxidil, and nutraceuticals seems to be an effective and safe treatment for androgenetic alopecia. This study has several limitations; chief among them is the small number of patients per group. Another limitation is that the possible additive or complementary effect of topical minoxidil or nutraceuticals could not be quantified. Prospective, well-designed controlled clinical trials are needed to better understand the complementary effects of different AGA therapies.

CONFLICT OF INTEREST

The authors declare no conflict of interest.

AUTHOR CONTRIBUTIONS

All of the authors have equally contributed to this manuscript.

ETHICAL APPROVAL

All procedures performed in studies involving human participants were in accordance with the ethical standards of the 1964 Helsinki Declaration and its later amendments or comparable ethical standards.

PATIENT CONSENT

All patients signed the informed consent form after understanding the nature of the trial.

DATA AVAILABILITY STATEMENT

The data that support the findings of this study are available on request from the corresponding author. The data are not publicly available due to privacy or ethical restrictions.

ORCID

Doris Day  <https://orcid.org/0000-0002-8773-479X>

Madison McCarthy  <https://orcid.org/0000-0003-0570-2864>

Iva Talaber  <https://orcid.org/0000-0002-0067-4959>

REFERENCES

1. Fan SMY, Cheng YP, Lee MY, Lin SJ, Chiu HY. Efficacy and safety of a low-level light therapy for androgenetic alopecia: a 24-week, randomized, double-blind, self-comparison, sham device-controlled trial. *Dermatol Surg.* 2018;44(11):1411-1420. doi:<https://doi.org/10.1097/DSS.0000000000001577>
2. Afifi L, Maranda EL, Zarei M, et al. Low-level laser therapy as a treatment for androgenetic alopecia. *Lasers Surg Med.* 2017;49(1):27-39. doi:<https://doi.org/10.1002/lsm.22512>
3. Cash TF. The psychological effects of androgenetic alopecia in men. *J Am Acad Dermatol.* 1992;26(6):926-931. doi:[https://doi.org/10.1016/0190-9622\(92\)70134-2](https://doi.org/10.1016/0190-9622(92)70134-2)
4. Han S-H, Byun J-W, Lee W-S, et al. Quality of life assessment in male patients with androgenetic alopecia: result of a prospective, multicenter study. *Ann Dermatol.* 2012;24(3):311-318. doi:<https://doi.org/10.5021/ad.2012.24.3.311>
5. Sonthalia S. Hair restoration in androgenetic alopecia: looking beyond minoxidil, finasteride and hair transplantation. *J Cosmetol Trichol.* 2016;02(01): doi:<https://doi.org/10.4172/2471-9323.1000105>
6. Katzer T, Leite Junior A, Beck R, da Silva C. Physiopathology and current treatments of androgenetic alopecia: Going beyond androgens and anti-androgens. *Dermatol Ther.* 2019;32(5):e13059. doi:<https://doi.org/10.1111/dth.13059>
7. Liu K-H, Liu D, Chen Y-T, Chin S-Y. Comparative effectiveness of low-level laser therapy for adult androgenic alopecia: a system review and meta-analysis of randomized controlled trials. *Lasers Med Sci.* 2019;34(6):1063-1069; doi:<https://doi.org/10.1007/s10103-019-02723-6>
8. Avci P, Gupta GK, Clark J, Wikonkal N, Hamblin MR. Low-level laser (light) therapy (LLLT) for treatment of hair loss. *Lasers Surg Med.* 2014;46(2):144-151. doi:<https://doi.org/10.1002/lsm.22170>
9. Kim W-S, Lee HI, Lee JW, et al. Fractional photothermolysis laser treatment of male pattern hair loss. *Dermatologic Surg.* 2011;37(1):41-51. doi:<https://doi.org/10.1111/j.1524-4725.2010.01833.x>
10. Ke J, Guan H, Li S, Xu L, Zhang L, Erbium YY. YAG laser (2,940 nm) treatment stimulates hair growth through upregulating Wnt 10b and β -catenin expression in C57BL/6 mice. *Int J Clin Exp Med.* 2015;8(11):20883-20889. Accessed November 29, 2020. www.ijcem.com/

11. Bae JM, Jung HM, Goo B, Park YM. Hair regrowth through wound healing process after ablative fractional laser treatment in a murine model. *Lasers Surg Med*. 2015;47(5):433-440. doi:<https://doi.org/10.1002/lsm.22358>
12. Avram MR, Leonard RT, Epstein ES, Williams JL, Bauman AJ. The current role of laser/light sources in the treatment of male and female pattern hair loss. *J Cosmet Laser Ther*. 2007;9(1):27-28. doi:<https://doi.org/10.1080/14764170601134479>
13. Bin CS, Goo BL, Zheng Z, Yoo KH, Kang J-S, Kim H. Therapeutic efficacy and safety of a 1927-nm fractionated thulium laser on pattern hair loss: an evaluator-blinded, split-scalp study. *Lasers Med Sci*. 2018;33(4):851-859. doi:<https://doi.org/10.1007/s10103-018-2437-5>
14. Meehphansan J, Ungpraphakorn N, Ponnikorn S, Suchonwanit P, Poovorawan Y. Efficacy of 1,550-nm erbium-glass fractional laser treatment and its effect on the expression of insulin-like growth factor 1 and Wnt/b-catenin in androgenetic alopecia. *Dermatol Surg*. 2018;44(10):1295-1303. doi:<https://doi.org/10.1097/DSS.0000000000001619>
15. Esmat SM, Hegazy RA, Gawdat HI, et al. Low level light-minoxidil 5% combination versus either therapeutic modality alone in management of female patterned hair loss: a randomized controlled study. *Lasers Surg Med*. 2017;49(9):835-843. doi:<https://doi.org/10.1002/lsm.22684>
16. Suchonwanit P, Rojhirunsakool S, Khunkhet S. A randomized, investigator-blinded, controlled, split-scalp study of the efficacy and safety of a 1550-nm fractional erbium-glass laser, used in combination with topical 5% minoxidil versus 5% minoxidil alone, for the treatment of androgenetic alopecia. *Lasers Med Sci*. 2019;34(9):1857-1864. doi:<https://doi.org/10.1007/s10103-019-02783-8>
17. Huang Y, Zhuo F, Li L. Enhancing hair growth in male androgenetic alopecia by a combination of fractional CO2 laser therapy and hair growth factors. *Lasers Med Sci*. 2017;32(8):1711-1718. doi:<https://doi.org/10.1007/s10103-017-2232-8>
18. Cohen PR. Laser-assisted drug delivery for the treatment of androgenetic alopecia: ablative laser fractional photothermolysis to enhance cutaneous topical delivery of platelet-rich plasma - with or without concurrent bimatoprost and/or minoxidil. *Dermatol Online J*. 2019;25(2):1-7. <https://escholarship.org/uc/item/7z43d5h4>
19. Gentile P, Garcovich S. Autologous activated platelet-rich plasma (AA-PRP) and non-activated (A-PRP) in hair growth: a retrospective, blinded, randomized evaluation in androgenetic alopecia. *Expert Opin Biol Ther*. 2020;20(3):327-337. doi:<https://doi.org/10.1080/14712598.2020.1724951>
20. Ho A, Sukhdeo K, Lo Sicco K, Shapiro J. Trichologic response of platelet-rich plasma in androgenetic alopecia is maintained during combination therapy. *J Am Acad Dermatol*. 2020;82(2):478-479. doi:<https://doi.org/10.1016/j.jaad.2018.03.022>
21. Emer J. Platelet-Rich Plasma (PRP): current applications in dermatology. *Skin Therapy Lett*. 2019;24(5):1-6.
22. Gentile P, Garcovich S. Systematic review of platelet-rich plasma use in androgenetic alopecia compared with minoxidil®, finasteride® and adult stem cell-based therapy. *Int J Mol Sci*. 2020;21(8):1-26. doi:<https://doi.org/10.3390/ijms21082702>
23. Lukač M, Lozar A, Perhavec T, Bajd F. Variable heat shock response model for medical laser procedures. *Lasers Med Sci*. 2019;34(6):1147-1158. doi:<https://doi.org/10.1007/s10103-018-02704-1>
24. Shanina NA, Patrushev AV, Zorman A. Histological and immunohistochemical changes in facial skin treated with combined ablative and non-ablative laser therapy. *J Cosmet Dermatol*. 2021. doi:<https://doi.org/10.1111/jocd.14023>
25. Lee GY, Lee SJ, Kim WS. The effect of a 1550 nm fractional erbium-glass laser in female pattern hair loss. *J Eur Acad Dermatol Venereol*. 2011;25(12):1450-1454. doi:<https://doi.org/10.1111/j.1468-3083.2011.04183.x>
26. Shah KB, Shah AN, Solanki RB, Raval RC. A comparative study of microneedling with platelet-rich plasma plus topical minoxidil (5%) and topical minoxidil (5%) alone in androgenetic alopecia. *Int J Trichology*. 2017;9(1):14.
27. Perper M, Aldahan AS, Fayne RA, Emerson CP, Nouri K. Efficacy of fractional lasers in treating alopecia: a literature review. *Lasers Med Sci*. 2017;32(8):1919-1925. doi:<https://doi.org/10.1007/s10103-017-2306-7>
28. Zheng Z, Kang HY, Lee S, Kang SW, Goo B, Bin CS. Up-regulation of fibroblast growth factor (FGF) 9 expression and FGF-WNT/ β -catenin signaling in laser-induced wound healing. *Wound Repair Regen*. 2014;22(5):660-665. doi:<https://doi.org/10.1111/wrr.12212>
29. Munck A, Gavazzoni MF, Trüeb RM. Use of low-level laser therapy as monotherapy or concomitant therapy for male and female Androgenetic alopecia. *Int J Trichology*. 2014;6(2):45-49. doi:<https://doi.org/10.4103/0974-7753.138584>
30. Kachhawa D, Vats G, Sonare D, Rao P, Khuraiya S, Kataiya R. A split head study of efficacy of placebo versus platelet-rich plasma injections in the treatment of androgenic alopecia. *J Cutan Aesthet Surg*. 2017;10(2):86-89. doi:https://doi.org/10.4103/JCAS.JCAS_50_16
31. Gkini M-A, Kouskoukis A-E, Tripsianis G, Rigopoulos D, Kouskoukis K. Study of platelet-rich plasma injections in the treatment of androgenetic alopecia through an one-year period. *J Cutan Aesthet Surg*. 2014;7(4):213-219. doi:<https://doi.org/10.4103/0974-2077.150743>
32. Maksimov DV. Experience in treatment of androgenetic alopecia using Er: YAG laser - case report. *J Laser Heal Acad*. 2021;1:1-2.
33. Mercik G, Chia LMG. New possibilities of androgenetic alopecia treatment with the Er:YAG laser. *Dermatologia Estet*. 2019;21(3):179-185.

How to cite this article: Day D, McCarthy M, Talaber I. Non-ablative Er:YAG laser is an effective tool in the treatment arsenal of androgenetic alopecia. *J Cosmet Dermatol*. 2021;00:1-8. <https://doi.org/10.1111/jocd.14370>