



High Precision Ablation of Benign Skin Lesions

Anže Zorman, MD

Introduction:

Many different benign skin lesions cause aesthetic problems for patients; fibromas, seborrheic keratosis, viral warts, skin tags, xanthelasma, millia, sebaceous hyperplasia, etc. All of these lesions can be very small, hence a high precision tool has to be used in order to achieve complete removal with minimal damage to surrounding tissue.

We are presenting a patient with two aesthetically problematic benign facial lesions. Skin tags are small benign tumors that form primarily in areas where the skin forms. They are quite often found on the eyelids and are typically the size of a grain of rice. Women are more likely to develop skin tags, and studies have shown an approximately 50% prevalence in the general population. Removal with a high-precision instrument allows for minimal tissue damage and downtime, and practically zero chances of adverse side effects.

Millia are another common aesthetic complaint that demands precise removal. Due to a clog in the eccrine sweat gland, a keratin-filled cyst appears, usually around the nose or eyes. A high-precision laser handpiece offers great way to completely remove millia, with very high patient satisfaction.

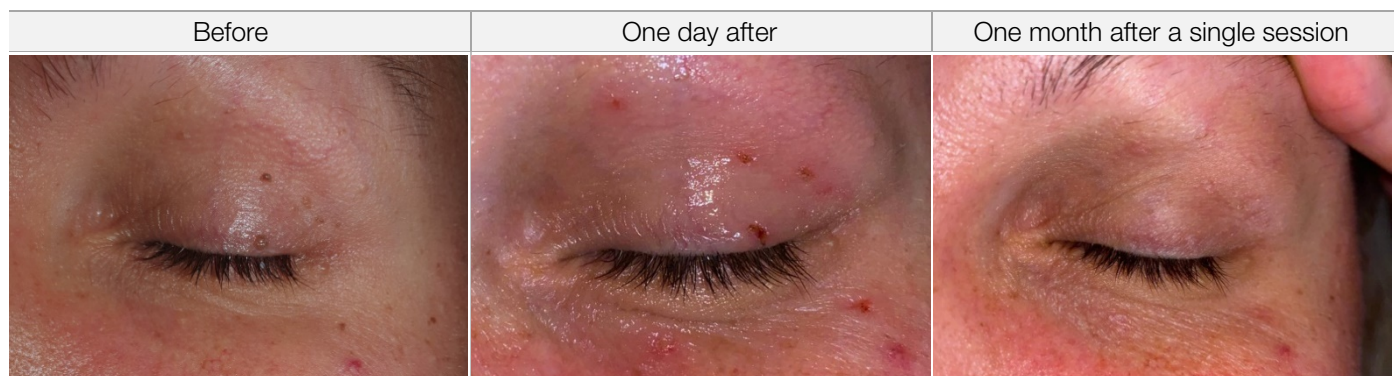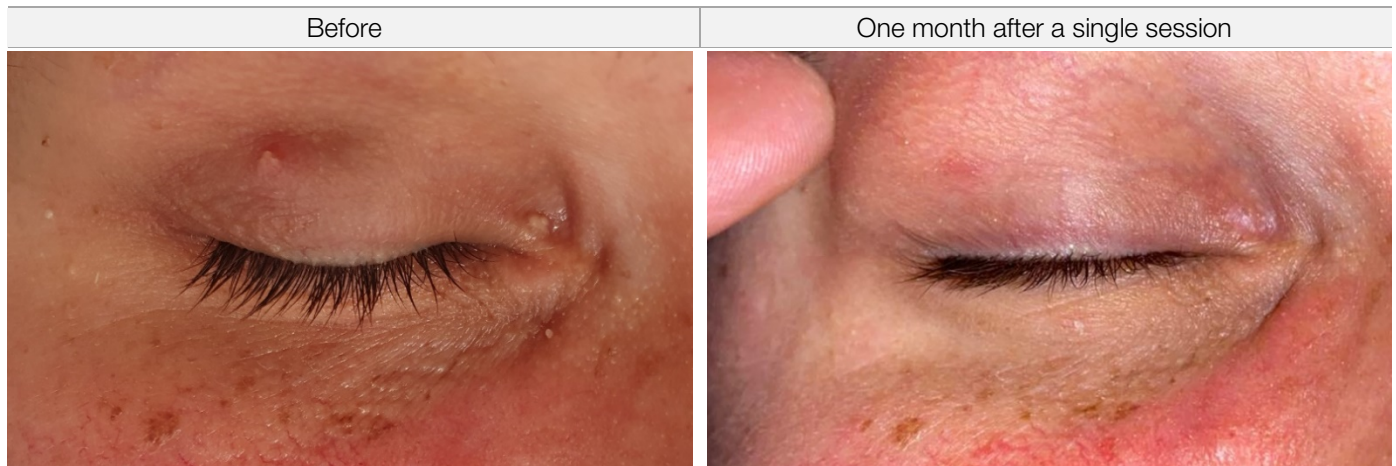
Laser	SP Dynamis
Wavelength	2940 nm Er:YAG
Handpiece	HC14-NE
Energy	80-100 mJ
Mode	MSP
Frequency	10 Hz
Fiber tip	Cylindrical 1300/8
Sessions	Single session



Dr. Anze Zorman graduated from the Medical University of Ljubljana, Slovenia. He did his internship at the Medical Center Novo Mesto, Slovenia and from 2013 to 2015 practiced medicine at the Health Center Sežana as a General Practitioner and Emergency Doctor. He joined Fotona in 2015 as clinical expert specializing in dermatology, aesthetics and surgery. Since then Dr. Zorman has been involved in the development of new applications and user education. He is also a researcher and regular lecturer for LA&HA.

CLINICAL CASE:

A patient in her 40's came to the clinic wanting to remove all of the facial skin tags and other lesions that caused her discomfort when she looked in the mirror. Er:YAG laser removal with a fiber-tip handpiece was used. All of the areas were anaesthetized with topical anesthetic cream (20% benzocaine, 6% lidocaine, 4% tetracaine) half an hour before the treatment. All lesions were removed with multiple passes over the lesions until complete clearance was achieved. The patient reported an overall pain level of 3/10, and 5/10 for one skin tag on the lower border of the upper eyelid. There was minimal bleeding during and almost none after the procedure. Antibiotic cream (gentamicin) was used immediately after the removal and a reepithelization cream for home use over the next 5 days. The patient reported slight swelling and few scabs for 2 days after the treatment.



Published by the Laser and Health Academy. All rights reserved. © 2021

Disclaimer: The intent of this Laser and Health Academy publication is to facilitate an exchange of information on the views, research results, and clinical experiences within the medical laser community. The contents of this publication are the sole responsibility of the authors and may not in any circumstances be regarded as official product information by the medical equipment manufacturers. When in doubt please check with the manufacturers whether a specific product or application has been approved or cleared to be marketed and sold in your country.

