




Xanthelasma Removal

Anže Zorman, MD

Introduction:

Xanthelasma palpebrarum is a very common benign lesion consisting of fat deposits formed around the eyes. It mainly presents as an aesthetic problem without any health concern to the patient. Laser treatments provide a minimally invasive option compared with conventional surgical procedures (with or without blepharoplasty). Er:YAG laser combines a good effect and low downtime with minimal side effects, especially when a high-precision laser handpiece is used.

Laser	SP Dynamis
Wavelength	2940 nm Er:YAG
Handpiece	H14-NE
Energy	100 mJ
Mode	MSP
Frequency	5 - 10 Hz
Fiber tip	Conical 1300/8
Sessions	Single session

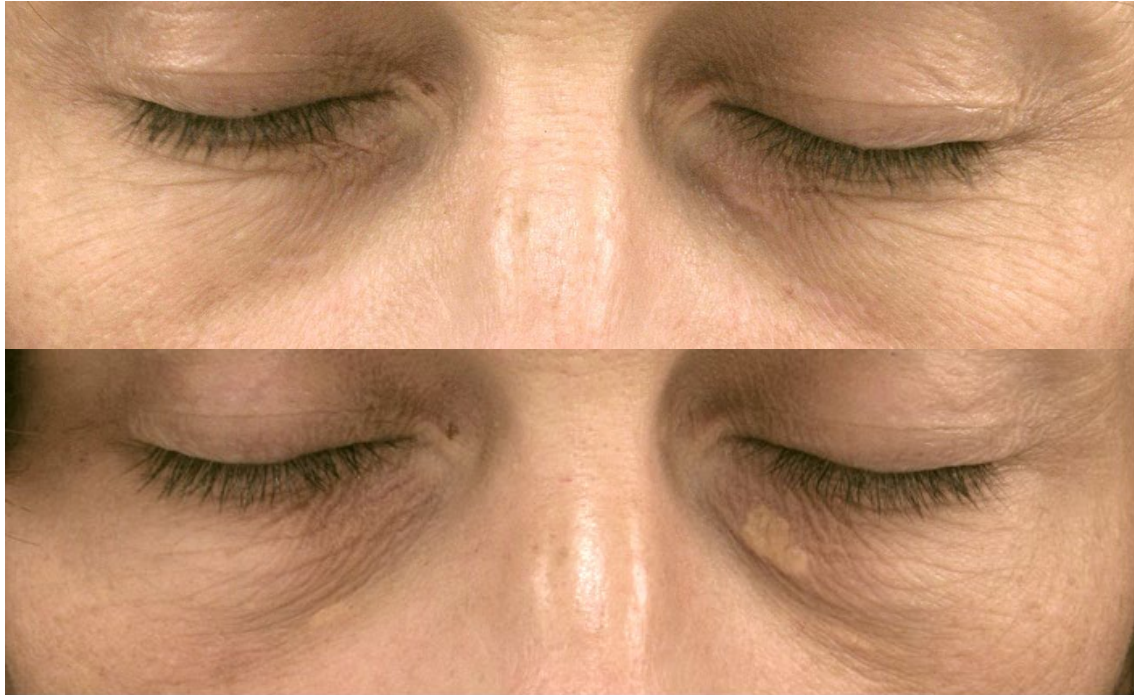

Dr. Anze Zorman graduated from the Medical University of Ljubljana, Slovenia. He did his internship at the Medical Center Novo Mesto, Slovenia and from 2013 to 2015 practiced medicine at the Health Center Sežana as a General Practitioner and Emergency Doctor. He joined Fotona in 2015 as a clinical expert specializing in dermatology, aesthetics and surgery. Since then Dr. Zorman has been involved in the development of new applications and user education. In addition to being a researcher and regular lecturer for LA&HA, he is also working at the private laser aesthetic center Medilase in Ljubljana, Slovenia for the last 5 years.

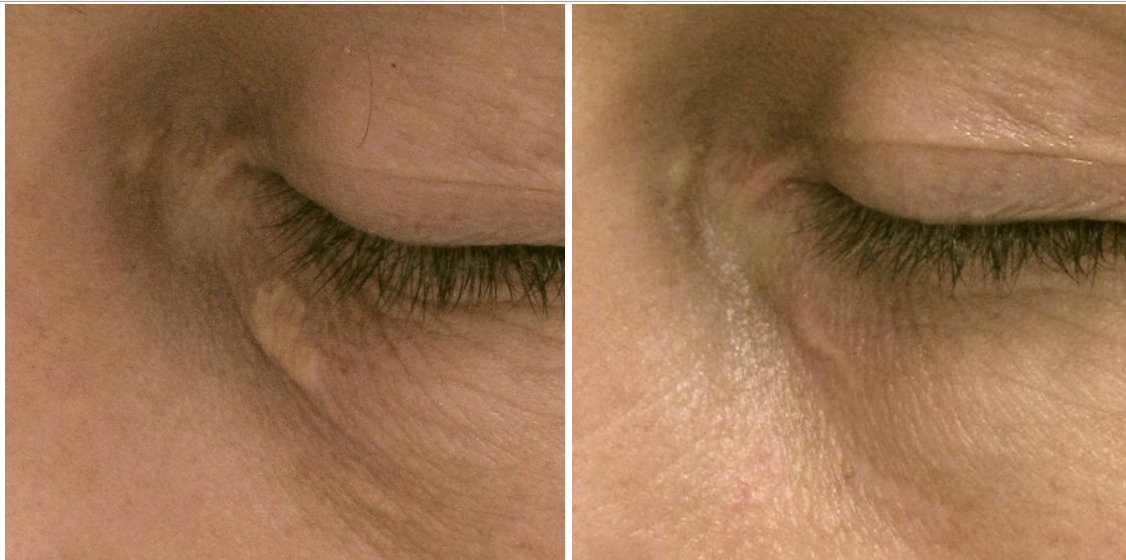CLINICAL CASE:

A patient in her 40's presented to the clinic with an unrelated problem and when informed that her "lesions under the eyes" could be removed, she immediately decided to undergo the procedure. About 30 min before the procedure, topical anesthetic cream was applied and then removed immediately before the laser procedure. A novel high-precision fiber-tip handpiece (H14-NE) was used with a conical fiber tip (diameter 0.6 mm). All 3 lesions were removed with multiple passes over the lesions until complete clearance was achieved. The patient reported a pain level of 4/10. There was minimal bleeding during and almost none after the procedure. Topical antibiotic cream (gentamicin) was applied and patient was encouraged to reapply this 2-3 times daily for the next 5 days. Regenerating cream (Bepanthen) was recommended for day 6 and onwards. The patient reported scabbing that lasted about 4-5 days and then erythema that lasted but gradually faded in the following weeks.

Before and after 2 months (frontal)



Before and after 2 months (close-up)



Published by the Laser and Health Academy. All rights reserved. © 2020

Disclaimer: The intent of this Laser and Health Academy publication is to facilitate an exchange of information on the views, research results, and clinical experiences within the medical laser community. The contents of this publication are the sole responsibility of the authors and may not in any circumstances be regarded as official product information by the medical equipment manufacturers. When in doubt please check with the manufacturers whether a specific product or application has been approved or cleared to be marketed and sold in your country.